

Chapter 20: Liver Transplantation

DEIRDRE A. KELLY AND DAVID MAYER

- Indications for liver transplantation, 378
 - Chronic liver disease, 378
 - Acute liver failure, 381
 - Inborn errors of metabolism, 382
 - Liver tumours, 383
- Pretransplant evaluation, 383
 - Pretransplant assessment of severity of liver disease, 383
- Contraindications for transplantation, 385
- Preparation for transplantation, 385
 - Immunization, 385
 - Management of hepatic complications, 385
 - Nutritional support, 386
 - Psychological preparation, 386
 - On the waiting list, 386
- Liver transplant surgery, 386
 - The role of the transplant co-ordinator, 387
 - The liver graft, 387
 - The donor operation, 387
 - The back table operation, liver reduction and liver splitting, 387
 - The recipient operation, 388
 - Living related liver transplantation, 389
 - Auxiliary liver transplantation, 389
- Postoperative management, 390
 - Ventilation, 390
 - Fluid management, 390
 - Immunosuppression, 390
 - Prophylactic antibiotics, 391
 - Other medications, 391
- Postoperative complications, 391
 - Early postoperative complications, 391
 - Complications after the first postoperative week, 392
 - Late complications post-liver transplant, 393
- Survival following liver transplantation, 394
 - Factors affecting survival, 394
 - Quality of life post transplant, 395
 - Growth post transplant, 395
 - Psychosocial development, 396
 - Endocrine development, 396
 - Family functioning, 396
 - Out-patient monitoring, 397

The successful development of paediatric liver transplantation has dramatically changed the prognosis for many babies and children dying of end-stage liver failure and is now accepted therapy for this condition.

The most important elements in improving survival post-liver transplantation have been:

- 1 Better preoperative management of hepatic complications and nutritional support.
- 2 Innovative surgical techniques to expand the donor pool.
- 3 Improvements in postoperative immunosuppression.

The consequent improvement in survival rate has extended the range of indications for liver transplantation in children to include semi-elective liver replacement, transplantation for metabolic liver disease and unresectable hepatic tumours. Increasing experience has also refined the precise indications for liver transplantation. As short-term survival has improved, interest has focused on quality of life and long-term survival.

Indications for liver transplantation

Liver transplantation is standard therapy for acute or chronic liver failure (Table 20.1).

Chronic liver disease

Neonatal liver disease

Biliary atresia remains the commonest indication for liver transplantation in children, accounting for 74% of children undergoing transplant below the age of 2 years (European Liver Transplant Registry 2002). Despite the professional emphasis on early diagnosis and management of this condition, in practice many children are still referred too late to benefit from a palliative Kasai portoenterostomy (Chapters 4 and 18). Urgent transplantation is required for those children who have an unsuccessful Kasai portoenterostomy or who develop nutritional or hepatic complications (Beath *et al.* 1993a).

Cholestatic liver disease

The outcome of cholestatic liver disease in infancy, such as Alagille's syndrome, non-syndromic biliary hypoplasia, familial intrahepatic cholestasis, is variable. Liver transplantation is indicated for the development of cirrhosis and portal hypertension, development of malnutrition or growth failure unresponsive to nutritional support, or intractable pruritus which is resistant to maximum medical therapy or biliary diversion (Whittington *et al.* 1994).

Table 20.1 Indications for liver transplantation.

<i>Chronic liver failure</i>
Neonatal liver disease
Biliary atresia
Idiopathic neonatal hepatitis
Cholestatic liver disease
Alagille's syndrome
Familial intrahepatic cholestasis (FIC)
Non-syndromic biliary hypoplasia
Inherited metabolic liver disease
α_1 -Antitrypsin deficiency
Cystic fibrosis
Glycogen storage type IV
Tyrosinaemia type I
Wilson's disease
Chronic hepatitis
Autoimmune
Idiopathic
Postviral (hepatitis B, C, other)
Other
Cryptogenic cirrhosis
Fibropolycystic liver disease +/- Caroli syndrome
<i>Acute liver failure</i>
Fulminant hepatitis
Autoimmune
Halothane exposure
Paracetamol poisoning
Viral hepatitis (A, B, C, E, or NA-G)
Metabolic liver disease
Fatty acid oxidation defects
Neonatal haemochromatosis
Tyrosinaemia type I
Wilson's disease
<i>Inborn errors of metabolism</i>
Crigler-Najjar type I
Familial hypercholesterolaemia
Primary oxalosis
Organic acidaemia
Urea cycle defects
<i>Liver tumours</i>
Benign tumours
Unresectable malignant tumours

Inherited metabolic liver disease

α_1 -Antitrypsin deficiency is the commonest form of inherited metabolic liver disease presenting in childhood in Europe. Although 50–70% of children may develop persistent liver disease progressing to cirrhosis, only 20–30% require transplantation in childhood (Filipponi *et al.* 1994; Francavilla *et al.* 2000). The management of tyrosinaemia type I has changed dramatically since the introduction of NTBC [2-(2-nitro-4-trifluoromethylbenzoyl)-1,3-cyclohexenedione], which prevents the formation of toxic metabolites and produces rapid clinical improvement. Use of this drug

has altered the natural history of the disease and the indications for transplantation (Burdelski *et al.* 1991; Lindstedt *et al.* 1992; Mohan *et al.* 1999). Prior to the introduction of NTBC, liver transplantation was indicated for acute or chronic liver failure, the development of hepatic dysplasia or hepatocellular carcinoma (HCC). Liver transplantation is now only indicated for those children who have a poor quality of life, do not respond to NTBC, or in whom hepatic malignancy is thought to have developed (Dionisi-Vici *et al.* 1997) (Chapter 5). Routine monitoring of children with tyrosinaemia type I being treated with NTBC includes ultrasound, computed tomography (CT) scan or magnetic resonance imaging (MRI) to detect the development of nodules and/or early HCC in association with regular α -fetoprotein levels. A persistent or sustained rise of α -fetoprotein may indicate the early development of HCC, which should be confirmed by the detection of hepatic dysplasia on liver biopsy (Macvicar *et al.* 1990; Manowski *et al.* 1990).

Wilson's disease is a rare indication for liver transplantation in childhood (Chapter 13) but is indicated for those children who present with advanced liver disease (Wilson score >6), fulminant liver failure or who have progressive hepatic disease despite penicillamine therapy (Nazer *et al.* 1986; Rela *et al.* 1993).

As long-term survival improves in children with cystic fibrosis (CF), liver transplantation has become a viable alternative and is now the commonest indication in adolescents in some centres. Hepatic decompensation is a late feature of CF liver disease, but portal hypertension is common and bleeding from oesophageal varices may be a serious recurrent problem. Selection for liver transplantation is indicated only for those children with hepatic decompensation (falling serum albumin, prolonged coagulation unresponsive to vitamin K), severe malnutrition or complications of portal hypertension unresponsive to medical management—ascites or uncontrolled variceal bleeding (Debray *et al.* 1999). Careful assessment of pulmonary function is required as severe lung disease (<50% of lung function) may indicate the necessity for a heart, lung and liver transplant (Couetil *et al.* 1997). Thus, early liver transplantation is indicated for those children with moderate lung disease prior to the development of significant irreversible lung disease (Milkiewicz *et al.* 2002). Preoperative management of respiratory disease is important and should include vigorous physiotherapy, intravenous antibiotics and DNase. Postoperative antibiotics should be based on known bacterial colonization and antibiotic sensitivity.

The majority of children with glycogen storage disease type I should respond to appropriate medical and nutritional management. Transplantation is indicated only for those children who develop multiple hepatic adenomata or in whom metabolic control has a significant effect on quality of life. Glycogen storage disease types III and IV

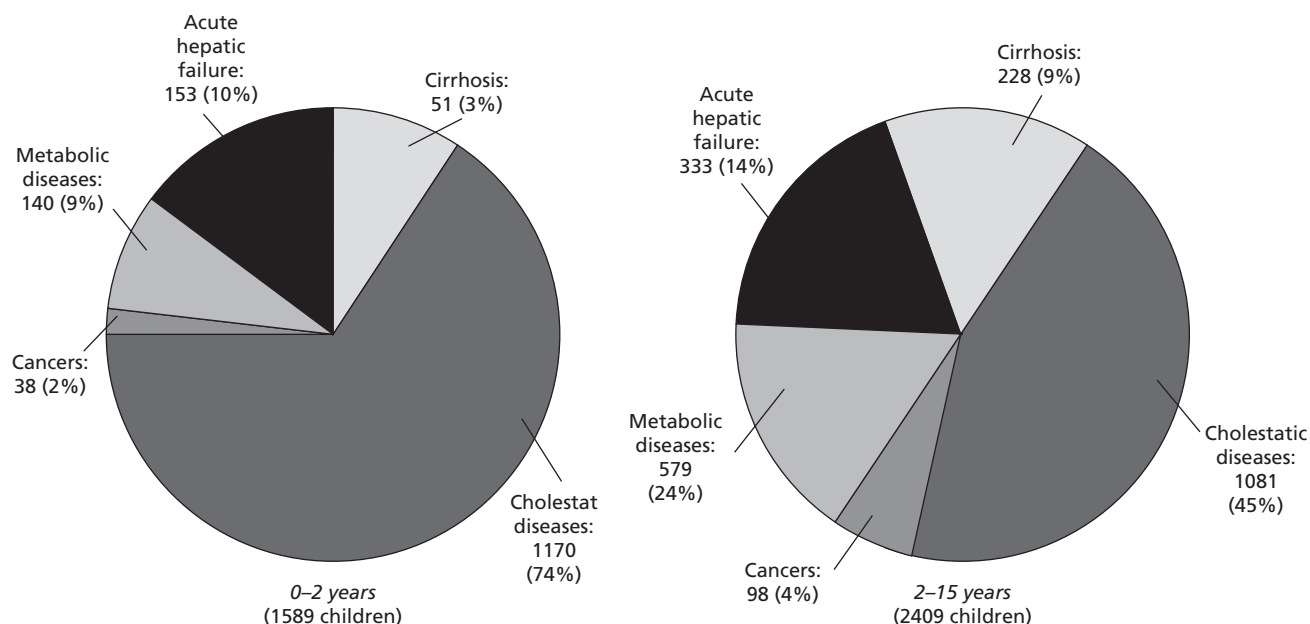


Fig. 20.1 Primary indication for liver transplantation in paediatric patients 1988–2001 (European Liver Transplant Registry).

may progress to cirrhosis and this may be an indication for transplantation because of hepatic dysfunction (Sokal *et al.* 1992).

Chronic hepatitis

Autoimmune liver disease types I and II The majority of children with autoimmune liver disease types I or II respond to immunosuppression with prednisolone or azathioprine (Chapter 8). Liver transplantation is indicated for those children who have advanced portal hypertension or do not respond to immunosuppression despite the use of second-line drugs such as cyclosporin A, tacrolimus and mycophenolate mofetil, or those who present with fulminant hepatic failure (Gregorio *et al.* 1997). Children with autoimmune hepatitis type II are more likely to present in fulminant hepatic failure and have an increased requirement for liver transplantation (Chapters 8 & 20).

Most children with chronic hepatitis B or C will be asymptomatic carriers in whom the development of cirrhosis, portal hypertension and/or HCC may evolve over 20–30 years. Although the main indication for transplantation is the development of chronic liver failure, recurrence with hepatitis B or C post-transplantation is likely in 90% of patients without prophylactic therapy, such as lamivudine or hepatitis B immunoglobulin (Bain *et al.* 1996).

Fibropolycystic liver disease

Fibropolycystic liver disease is a rare indication for liver transplantation in childhood, as liver function usually remains normal for many years in these children even if they develop severe portal hypertension. Liver replacement is only indicated if hepatic decompensation occurs in association with portal hypertension or hepatic enlargement interferes with quality of life. The disease may be associated with infantile polycystic kidney disease and thus, in some instances, both liver and kidney replacement will be required (Chapter 9).

Primary immunodeficiency

As bone marrow transplantation for primary immunodeficiency has become successful, it is clear that many children with these diseases have associated liver disease. The most common immunodeficiency is CD40 ligand deficiency (hyper IgM syndrome), in which recurrent cryptosporidial infection of the gut and biliary tree lead to sclerosing cholangitis. In this group of children it is important to carry out bone marrow transplantation before the development of significant liver disease or to consider combined liver and bone marrow transplantation if necessary (Hadzic 1999).

Timing of transplantation for children with chronic liver failure

As many children with cirrhosis and portal hypertension have well-compensated liver function, the timing of liver transplantation may be difficult to predict. Biochemical

decompensation can be predicted by studying the lidocaine metabolite monoethyl glycinexylide (MEGX) (Oellerich *et al.* 1990), as serial estimates of MEGX formation and excretion over time may be useful predictors in individual patients. In practice, the need for liver transplantation is indicated by a persistent rise in total bilirubin $>150\text{ mmol/l}$, prolongation of prothrombin ratio (INR >1.4) and a fall in serum albumin $<35\text{ g/l}$ (Malatack *et al.* 1987). These parameters have recently been evaluated in order to develop a Pediatric End-Stage Liver Disease Score (PELD) to predict death and have confirmed their accuracy. The PELD score was strengthened by the addition of growth failure and age (<1 year) to the above values (McDiarmid *et al.* 2002).

As protein-energy malnutrition is a known complication of chronic liver disease in the developing child, serial evaluation of nutritional parameters may be an alternative guide to early hepatic decompensation. Progressive reduction of fat stores (triceps skin fold) or protein stores (mid-arm muscle area) despite nutritional support usually predict hepatic decompensation (Beath *et al.* 1993b).

Children with complex hepatic complications such as chronic hepatic encephalopathy, refractory ascites, intractable pruritus or recurrent variceal bleeding despite optimum management require prompt referral for transplantation. Variceal haemorrhage which is not controlled by variceal banding or endoscopic sclerotherapy may be temporarily managed by the insertion of a transjugular intrahepatic portosystemic shunt (Chapters 3, 14 and 18). This technique reduces portal vein pressure and prevents variceal haemorrhage, allowing sufficient time for preoperative nutritional support and the search for an appropriate donor.

A particularly important aspect in the timing of liver transplantation is consideration of psychosocial development. Children with chronic liver disease have a significant reduction of developmental motor skills, which may be reversed following liver transplantation if performed early enough (Beath *et al.* 1993a, 1995). Thus, any significant delay in developmental parameters is an indication for referral for liver transplantation.

It is essential that children with chronic liver disease should be referred for transplantation before the complications of their liver disease adversely impair the quality of their lives and before growth and development are retarded.

Acute liver failure

The indications for liver transplantation for acute liver failure vary depending on whether the disease process is due to fulminant hepatitis or secondary to an inborn error of metabolism (Chapters 5 and 7). In general, children with acute liver failure should be referred early to a specialist unit with facilities for transplantation in order to

provide time for stabilization and to find an appropriate donor organ.

Fulminant hepatitis

There are four main aims in the management of children with fulminant hepatitis requiring transplantation:

- 1 To assess prognosis for recovery or liver transplantation.
- 2 Prevent or treat hepatic complications while awaiting a donor organ/regeneration of native liver.
- 3 Provide hepatic support.
- 4 Provide psychosocial support and information for parents.

The current information on prognosis of children with fulminant hepatitis is based on previous experience in the pretransplant era, information from adult studies, and more recently information from paediatric studies (O'Grady *et al.* 1989; Friedman *et al.* 1994; Lee *et al.* 2001).

Poor prognostic factors for children with fulminant hepatitis requiring listing for liver transplantation are as follows:

- non-A to G hepatitis
- rapid onset of coma with progression to grade III or IV hepatic coma
- diminishing liver size
- falling transaminases
- increasing bilirubin ($>300\text{ mmol/l}$)
- persistent coagulopathy ($>50\text{ s/control}$; INR >4).

Unlike adults, children with fulminant hepatitis may have severe coagulopathy but mild encephalopathy and therefore both are not required prior to listing for liver transplantation (Bonatti *et al.* 1997).

All children with grade III hepatic coma, or those who have a persistent coagulopathy (prothrombin ratio INR >4) and have no evidence of irreversible brain damage from cerebral oedema or hypoglycaemia should be listed for transplantation. As current medical management for cerebral oedema is unsatisfactory and methods of determining irreversible brain damage unreliable, this may be a difficult decision. Cerebral CT scans may detect gross cerebral oedema, haemorrhage or infarction; they may alter selection for transplantation but are not usually helpful in the early stages. Monitoring of cerebral oedema by measurement of intracranial pressure has improved the selection of recipients but not overall survival. Assessment of cerebral blood flow is not helpful as this may be reduced in hepatic failure, but assessment of cerebral perfusion pressure may be more sensitive (Chapter 7).

Electroencephalography (EEG) may demonstrate a reduction in electrical activity and ultimately brain death, although these results must be interpreted cautiously in ventilated patients or those treated with thiopentone as

the EEG tracing is affected by sedation and anaesthetic drugs.

Paracetamol poisoning

Selection of patients with paracetamol poisoning may be particularly difficult. Children and adolescents have a lower incidence of liver failure with paracetamol overdose than adults, possibly because of the effect of hepatic maturation and glutathione production (Lauterberg *et al.* 1980). Transplantation is more likely if the overdose was taken with another drug (e.g. LSD, Ecstasy) or with alcohol (Mahadevan *et al.* 1999).

Children should be considered for liver transplantation if there is a persistent coagulopathy (INR >4), metabolic acidosis (pH < 7.3), an elevated creatinine (>300 mmol/l) or rapid progression to hepatic coma grade III. In some children cerebral oedema may persist despite evidence of hepatic regeneration and recovery, and influence their postoperative recovery.

Metabolic liver disease

Acute liver failure may be the presenting feature of inherited metabolic liver disease such as Wilson's disease and tyrosinaemia type I (Chapters 5 and 13). The clinical presentation is more likely to be subacute and liver failure occurs in the presence of underlying cirrhosis. Selection for liver transplantation is on the basis of non-response to medication or severe coagulopathy as jaundice and encephalopathy may not be obvious (Nazer *et al.* 1986). Diminishing liver size does not occur because of the underlying cirrhosis.

Infants with neonatal haemochromatosis who present within days or weeks of birth with severe coagulopathy and encephalopathy may be candidates for liver transplantation if medical management using the 'antioxidant cocktail' has failed (Chapter 5) (Shamieh *et al.* 1993; Muiesan *et al.* 1995; Flynn *et al.* 2003).

Inborn errors of metabolism

Certain inborn errors of metabolism are secondary to hepatic enzyme deficiencies (Chapters 5 and 12). Liver transplantation is indicated for these conditions if the hepatic enzyme deficiency leads to:

- irreversible liver disease/liver failure and/or hepatoma
- severe extrahepatic disease.

Those diseases in which the inborn error of metabolism leads to liver failure (tyrosinaemia type I, Wilson's disease, or α_1 -antitrypsin deficiency; see above) are managed as acute or chronic liver failure.

Severe extrahepatic disease

In these diseases (Table 20.1) the liver functions normally but the missing hepatic enzyme leads to severe extrahepatic disease such as kernicterus in Crigler–Najjar type I, coronary artery disease in familial hypercholesterolaemia, and systemic oxalosis in primary oxaluria.

Selection for transplantation is difficult. It is important to evaluate the quality of life of the child on medical management and to consider the potential mortality and morbidity of the primary disease in comparison with the risks, complications and outcome following liver transplantation (Burdelski *et al.* 1991).

The timing of transplantation in these disorders depends on:

- 1 The rate of progression of the disease.
- 2 Quality of life of the affected child.
- 3 The development of severe irreversible extrahepatic disease.

Crigler–Najjar type I

The timing of transplantation for this inherited disorder of unconjugated hyperbilirubinaemia depends on:

- 1 The quality of the child's life, i.e. how many hours of phototherapy per day are required to control the unconjugated bilirubin levels.
- 2 The potential development of irreversible structural brain damage secondary to kernicterus.

In general it is appropriate to transplant these children between the ages of 3 and 5 years in order to reduce disruption to their education. The most appropriate transplant operation for these children is now auxiliary liver transplantation (see below) (Rela *et al.* 1997).

Organic acidaemia

Children with propionic acidaemia or methylmalonic acidaemia are at lifelong risk of recurrent metabolic acidosis and long term brain damage. Liver replacement is considered palliative treatment for these conditions as the enzyme deficiency affects all body tissue. It should be considered early for children who have a particularly severe phenotype or family history (Chapter 5). Very careful preoperative management, including preoperative dialysis and perioperative haemofiltration to control acidosis, is essential to ensure good operative control. Until recently, orthotopic liver replacement has been considered necessary to provide adequate enzyme supplementation. It is possible that auxiliary liver transplantation may be sufficient for mildly affected patients (Rela *et al.* 1997).

Familial hypercholesterolaemia

Children who are homozygous are prone to premature development of coronary artery disease and thus should be transplanted before coronary artery disease is irreversible. In view of recent progress with gene therapy for this condition, auxiliary liver transplantation or gene therapy may be more appropriate treatment strategies (Raper *et al.* 1996).

Primary oxalosis

Ideally liver replacement in this condition should be prior to the development of severe irreversible renal failure. As this is often not possible, liver and kidney replacement may be required simultaneously (Ellis *et al.* 2001). As deficiency of the enzyme alanine glyoxylate aminotransferase results in an overproduction of oxalate, these children are not suitable for auxiliary liver transplantation.

Liver tumours

Potential indications for liver tumours include unresectable benign tumours causing hepatic dysfunction, and unresectable malignant tumours (hepatoblastoma or HCC) which are refractory to chemotherapy without evidence of extrahepatic metastases (Chapter 19).

The preoperative evaluation should include a meticulous search for extrahepatic metastases, with CT scanning of chest and abdomen and regular monitoring of serum α -fetoprotein to detect relapse or recurrence outside the liver; and careful assessment of cardiac function because of the cardiotoxic effects of drugs such as daunorubicin. The timing of transplantation is crucial and is best planned electively during the course of chemotherapy or at completion (Pimpalwar *et al.* 2002). Bone marrow suppression at the time of transplantation is supported with administration of granulocyte-stimulating factors.

Children with rhabdomyosarcomas are usually unsuitable for transplantation because of the extent of the tumour and presence of extrahepatic metastases (Chapter 19).

Pretransplant evaluation (Table 20.2)

Evaluation of the patient before transplantation should:

- 1 Assess the severity of the liver disease and the presence or absence of hepatic complications.
- 2 Establish the urgency for transplantation.
- 3 Assess whether the operation is technically feasible.
- 4 Consider any significant contraindications to successful transplantation.

Table 20.2 Pretransplant assessment.

Nutritional status	Height, weight, triceps skinfold, mid-arm muscle area
Identification of hepatic complications	Ascites, hepatosplenomegaly, varices on endoscopy
Cardiac assessment	ECG, echo, chest X-ray (cardiac catheterization if required)
Respiratory function	Oxygen saturation*, ventilation perfusion scan*, lung function tests†
Neurological and developmental assessment	EEG, Bayley developmental scales, Stanford–Binet intelligence scales
Renal function	Urea, creatinine, electrolytes Urinary protein/creatinine ratio Cr EDTA (if available)
Dental assessment	
Radiology	Ultrasound of liver and spleen for vascular anatomy Wrist X-ray for bone age and rickets MRI/angiography‡
Serology	Cytomegalovirus Epstein–Barr virus Varicella zoster Herpes simplex Hepatitis A, B, C HIV Measles
Haematology	Full blood count, platelets, blood group

*If cyanosed.

†In cystic fibrosis.

‡If portal vein anatomy equivocal.

ECG, Electrocardiogram; EDTA, ethylenediamine tetraacetic acid; EEG, electroencephalogram; HIV, human immunodeficiency virus; MRI, magnetic resonance imaging.

5 Establish whether the transplant operation is appropriate for the child and family.

6 Prepare the child and family psychologically.

Pretransplant assessment of severity of liver disease

The indications for transplantation should be critically evaluated, the diagnosis should be reviewed, the prognosis should be considered and alternative medical or surgical therapy should be evaluated. It is essential to evaluate whether liver transplantation will improve the quality of life for both child and family.

Hepatic function

The histological diagnosis should be reviewed and if necessary liver histology should be obtained. The decision to list for transplantation is usually based on serial deterioration in hepatic function as indicated by:

- albumin (<35 g/l)
- coagulation time (INR >1.4)
- a rising bilirubin (>150 mmol/l).

The extent of portal hypertension may be estimated by establishing the size of the portal vein on ultrasound, and by visualizing oesophageal and gastric varices by gastrointestinal endoscopy, which also establishes the presence of gastritis and/or peptic ulceration.

Renal function

The main abnormalities of renal function in children with either acute or chronic liver failure include renal tubular acidosis, glomerulonephritis, acute tubular necrosis and hepatorenal syndrome. Careful assessment of renal function is necessary in order to plan modification for the potentially nephrotoxic effects of post-transplant immunosuppression and to assess the necessity of perioperative renal support.

Haematology

Full blood count, platelets, coagulation indices and blood group are obtained. HLA matching is not required.

Serology

It is important to establish immunity to previous infection (Table 20.2). As donor grafts are matched for cytomegalovirus (CMV) status if possible, assessment of previous infection with CMV is important. Children who are Epstein-Barr virus (EBV)-negative are more likely to develop a primary infection post transplant and have a higher risk of developing post-transplant lymphoproliferative disease.

Radiology

The most important technical information required is the vascular anatomy and patency of the hepatic vessels. Most of the necessary information is obtained by colour flow Doppler ultrasound examination of the liver and spleen. MRI or conventional angiography may be required to visualize abnormal anatomy such as the hypovascular syndrome or to determine the extent of portal vein thrombosis.

Evidence of retrograde flow and/or a small portal vein (<4 mm at the porta hepatis) suggests severe portal hypertension and increases the urgency for liver transplantation.

Children with congenital liver disease, such as biliary atresia, may have an increased incidence of abnormal vasculature. The hypovascular syndrome consists of an absent inferior vena cava, preduodenal or absent portal vein, azygous drainage from the liver and the polysplenia syndrome. It may be associated with situs inversus, dextrocardia or left atrial isomerism (Lilly & Starzl 1974). Angiography is advised to determine the position and size of these abnormal vessels.

Liver transplantation causes important haemodynamic changes during the operative and anhepatic phases. It is essential therefore to have baseline information on cardiac and respiration function. Most of the information required will be obvious from an ECG, echocardiogram or oxygen saturation.

Cardiac assessment

Particular attention should be paid to children who have congenital cardiac disease, for example atrial and ventricular septal defects which are associated with biliary atresia. Peripheral pulmonary stenosis is a known feature of Alagille's syndrome. Cardiomyopathy may develop secondary to tyrosinaemia type I and the organic acidaemias or as a result of chemotherapy of malignant tumours. Cardiac catheterization may be necessary to determine whether: (i) cardiac function is adequate to withstand the haemodynamic changes during the operation; (ii) corrective surgery is required preoperatively; or (iii) the cardiac defect is inoperable and liver transplantation is contraindicated.

Respiratory assessment

A minority of children with end-stage liver disease develop intrapulmonary shunts (hepatopulmonary syndrome). This potentially reversible complication of liver disease needs early consideration for liver transplantation. The clinical signs of cyanosis and digital clubbing indicate the need for pulmonary function studies, ventilation-perfusion scans, bubble echocardiography and/or cardiac catheterization (Hobeika *et al.* 1994; Uemoto *et al.* 1996).

Neurodevelopmental assessment

The aim of liver transplantation is to improve quality of life post transplant. Thus, it is necessary to identify any existing neurological or psychological defects which may not be reversible post transplantation. The psychological and developmental assessment of children with clinical liver disease may be performed using standard tests such as: the Griffiths developmental scale (for children under the age of 5 years) or the Bayley developmental scales or Stanford-Binet intelligence scales (children of all ages) (Wayman *et al.* 1997).

Dental assessment

Chronic liver disease has an adverse effect on the growth and development of young children, including their dentition. Clinical problems pretransplant include hypoplasia with staining of the teeth and gingival hyperplasia related to poor hygiene. As gingival hyperplasia may be a significant problem post transplant secondary to cyclosporin immunosuppression, it is important to establish good methods of dental hygiene prior to transplantation (Hosey *et al.* 1995) (Chapter 17).

Contraindications for transplantation

As surgical skills have improved there are fewer contraindications to liver transplantation based on technical restrictions. Portal vein thrombosis, age and size are no longer contraindications for transplantation (Beath *et al.* 1993a). However, experience has shown that certain medical conditions are not curable by transplantation. The contraindications for liver transplantation include:

- 1 The presence of severe systemic sepsis, particularly fungal sepsis, at the time of operation.
- 2 Malignant hepatic tumours with extrahepatic spread, because of rapid recurrence.
- 3 Severe extrahepatic disease which is not reversible following liver transplantation, e.g. severe cardiopulmonary disease for which corrective surgery is not possible, or severe structural brain damage.
- 4 Severe systemic oxalosis with cardiac involvement, as these children develop significant hypotension and do not withstand the haemodynamic disturbances post transplant.
- 5 Mitochondrial cytopathies with multisystem involvement (Thomson *et al.* 1998).
- 6 Alper's disease and valproate toxicity because of the progression of neurodegeneration.
- 7 Giant-cell hepatitis with autoimmune haemolytic syndrome because of disease recurrence.

Initially, human immunodeficiency virus (HIV) positivity was a contradiction to transplantation, but with current effective treatment regimes, HIV-positive children can now be considered if necessary. Although hepatitis B and C recur post transplant, postoperative therapy is possible and thus transplantation is acceptable. (Grellier *et al.* 1996; Araya *et al.* 1997).

Children with a higher risk at surgery include those with:

- previous surgery, because of technical difficulties with adhesions and potential small bowel perforation
- portal vein thrombosis, because vein grafts may be required.

Preparation for transplantation

Immunization

Live vaccines are usually contraindicated in the immunosuppressed child, and so it is important to ensure that routine immunizations are complete, for example diphtheria, pertussis, tetanus and polio, pneumovax for protection from streptococcal pneumonia, and Hib for protection against *Haemophilus influenzae*. In children older than 6 months, measles, mumps, rubella and varicella vaccination should be offered. Ideally hepatitis A and B vaccination should be prescribed pretransplant. Recent studies suggest that some live vaccines can be safely given post transplantation (Whittington *et al.* 1994).

Management of hepatic complications

The treatment of specific hepatic complications is an important part of preoperative management. Variceal bleeding should be managed as described elsewhere (see Chapters 14 and 18) with oesophageal banding or sclerotherapy, vasopressin or octreotide infusion.

Oesophageal banding is preferred to injection sclerotherapy for children on the active liver transplant list as the inevitable development of post-sclerotherapy variceal ulcers may be adversely affected by post-transplant immunosuppression (Reinoso *et al.* 1997). In children with uncontrolled variceal bleeding, the insertion of TIPSS (transjugular intrahepatic portosystemic stent-shunt) has proved an effective management strategy in older children (Chapters 14 and 18) (Johnson *et al.* 1996; Heyman & LaBerge 1999).

Sepsis, particularly ascending cholangitis and spontaneous bacterial peritonitis, requires effective treatment with appropriate broad-spectrum antibiotics. Cefuroxime (20 mg/kg/dose t.d.s.); amoxil (25 mg/kg/dose t.d.s.) and metronidazole (8 mg/kg/dose t.d.s.) are useful first-line drugs until bacterial cultures are positive. In children with acute liver failure, prophylactic antifungal therapy with either fluconazole or liposomal amphotericin is essential. Children should be suspended from the transplant list during episodes of significant sepsis.

Salt and water retention leading to ascites and cardiac failure should be effectively managed with diuretics and salt and water restriction. It is essential to consider intervention with haemodialysis and/or haemofiltration if acute renal failure or hepatorenal failure develop. Haemodialysis is rarely required in chronic liver failure unless there is acute decompensation, but haemodiafiltration may be necessary in acute liver failure to control cerebral oedema and/or coagulopathy. Preoperative haemodialysis and perioperative haemofiltration are

Table 20.3 Nutritional support in infants and children undergoing liver transplantation.*

Nutrient	Preoperative	Postoperative
Carbohydrate (g/kg/day)	Glucose polymer (15–20)	Glucose polymer (6–8)
Protein (g/kg/day)	Low salt protein (3–4)	Whole protein (2.5–3)
Fat (g/kg/day)	50–70% MCT (8)	80–90% LCT (5–6)
Energy intake (EAR)	120–150%	120%

*Best provided as a modular feed in infants and as calorie supplements in older children.

MCT, Medium-chain triglyceride; LCT, long-chain triglyceride; EAR, estimated average requirement.

essential for children undergoing transplantation for organic acidemia. Recent trials in adults have evaluated a modified dialysis method using a molecular absorbent recirculating system (MARS), which may improve short-term survival in end-stage liver failure. Trials have not yet been performed in children (Mitzner *et al.* 2000).

Nutritional support

A number of important advances in the understanding of the pathophysiology of malnutrition in liver disease have led to improved nutritional strategies and improved outcome post transplant. The aim of nutritional therapy is to maintain or improve nutritional status and thus improve morbidity and mortality post transplant. A high-calorie-protein feed, 150–200% of the recommended energy intake (EAR), is required (Table 20.3). It may be difficult to provide this high-energy intake with standard feeds, particularly in fluid-restricted children, thus a modular feed may be appropriate for young babies. It is usually necessary to provide these feeds by nocturnal nasogastric enteral feeding or continuous feeding. If enteral feeding is not tolerated, due to ascites, variceal bleeding or recurrent hepatic complications, parenteral nutrition in normal amounts is required. Although there may be reluctance to use amino acid and lipid solutions in this situation, the calorific value of these essential nutrients overcomes the potential problems of encephalopathy and lipid catabolism (Beath *et al.* 1993b).

Psychological preparation

The most important aspect of the transplant assessment is the psychological counselling and preparation of the child and family. A skilled multidisciplinary team, including play therapist and psychologist, is essential to the success of this preparation. Parents and appropriate relatives must be fully informed of the necessity for liver transplantation in their child and of the risks, complications and the long-term implications of the operation. Psychological preparation in children older than 2 years is essential and may be successfully achieved through in-

novative play therapy and toys and books suitable for children (Chapter 1).

Particularly careful counselling is necessary for parents of children who are being considered for liver transplantation because of an inborn error of metabolism. As their children are not dying from liver disease, these parents may find it more difficult to accept the risks and complications of the operation, the potential mortality and the necessity for long-term immunosuppression. Parents of children who require transplantation for acute liver failure may be too distressed fully to appreciate the significance and implications of liver transplantation and will require ongoing counselling and education postoperatively. Children who survive the liver transplant operation for acute liver failure should have postoperative counselling and play therapy to help them come to terms with their transplant.

On the waiting list

Many families find the waiting time pretransplant very stressful, and continued support from the multidisciplinary team is required. Mortality on the waiting list used to be as high as 25% prior to the development of reduction hepatectomy, which has dramatically reduced deaths on the waiting list to 5%. Although there are continual problems with donor shortages, particularly for small children, the development of living related liver transplantation and the split liver graft programme has alleviated this problem (De Ville de Goyet *et al.* 1993; Mirza *et al.* 1998; Millis *et al.* 2000).

Liver transplant surgery

Liver transplantation involves three operations—the donor operation, the back table operation, and the recipient operation. The logistics of co-ordinating these operations together with transplantation of other organs from the same multiorgan donor are complex, and the surgeon relies heavily upon the services of the transplant coordinators. The majority of liver grafts are retrieved from heart-beating cadavers, but can be obtained from live donors (see below).

The role of the transplant co-ordinator

Potential cadaveric organs are notified to the procurement co-ordinator, who is responsible for establishing their suitability for transplantation, co-ordinating the multidisciplinary procurement team and making arrangements at the donor hospital. Other duties include promotion of organ donation, education of health service professionals, and donor family support. The recipient co-ordinator is responsible for organizing the recipient operation, including travel arrangements for the patient, organization of theatres, anaesthesia, blood bank and intensive care, care of the recipient's family during the operation and postoperative follow-up.

The liver graft

The recipient is selected on the basis of a compatible blood group, size matching, medical urgency and time on the waiting list. Occasionally, blood group O may be given to blood groups A or B, if medically necessary. When possible, grafts from CMV-positive donors are not given to CMV-negative recipients, but medical urgency may dictate otherwise. Unlike the kidney, there is no benefit from HLA matching, and hyperacute rejection is exceptionally rare in liver transplantation even in the presence of a positive cytotoxic crossmatch.

Cadaver livers are retrieved from heart-beating donors that have fulfilled the criteria of brainstem death. Proper care of the donor is essential to maintain good-quality donor organs. Brainstem death results in loss of central regulatory mechanisms that control the cardiovascular, respiratory and endocrine systems. Donor resuscitation is directed at optimizing tissue perfusion and oxygenation, maintaining normal blood glucose and body temperature, and controlling sepsis. With the increasing demands for cadaver organs, previous constraints on donor suitability have been relaxed. There is no absolute age limit, although younger donors are preferable for paediatric recipients. Malignancy (except brain tumours) and uncontrolled bacterial sepsis or viral infections such as HIV remain absolute contraindications. Abnormal liver function tests may be misleading and thus the macroscopic appearance of the liver during organ retrieval is an important factor in selection. A hard fibrotic or frankly cirrhotic liver is clearly unusable, as is a grossly fatty liver. When in doubt, histological examination of a frozen section of the liver is essential.

The donor operation

The liver is retrieved from a cadaver donor as part of an integrated multiorgan operation in which the kidneys, heart and lungs and, on occasion, the pancreas, small bowel, corneas, skin and bone are also removed for trans-

plantation. The donor is maintained on a ventilator in the operating theatre until the moment of circulatory arrest. Paralysing agents are given to prevent spinal reflexes and broad-spectrum antibiotics to prevent infection. The organs are removed through a full-length midline incision. The liver is inspected with particular care to identify anomalous arterial anatomy. The porta hepatis is dissected, dividing the common bile duct close to the duodenum, and the common hepatic artery is traced to its origin from the aorta. The superior mesenteric vein is identified in the root of the mesentery and prepared for cannulation. The cardiothoracic organs are then mobilized and heparin administered to achieve full anticoagulation. At this stage ventilation is discontinued, the abdominal organs are perfused with ice-cold preservation solution, and the abdomen is packed with ice-slush to achieve rapid cooling. Once the cardiothoracic organs have been removed the liver dissection is completed. The hepatic artery is taken in continuity with a patch of aorta at the origin of the coeliac trunk. The portal vein is divided at its confluence with the superior mesenteric and splenic veins, the infrahepatic vena cava is divided just above the origins of the renal veins, and the suprahepatic vena cava is divided at its junction with the right atrium. After removal of the liver, the hepatic artery and portal vein are flushed again with preservation solution and the bile duct is rinsed free of bile. The liver, immersed in cold preservation solution, is hermetically sealed in plastic bags, and transported in a freezer box packed with ice. Iliac, splenic and superior mesenteric vessels are also removed since they may be required for vascular conduits in the recipient, especially if the liver is split (see below).

The back table operation, liver reduction and liver splitting

The back table operation is performed at the recipient hospital and is synchronized with the recipient operation. For a whole-liver graft, the back table operation is relatively straightforward; extraneous tissue is cleared from the graft and vascular pedicles checked for tributaries which require ligation. However, the majority of paediatric liver transplants require a liver reduction operation to be performed, to generate either a single reduced-size graft or a pair of split liver grafts.

The principles of liver reduction are based upon the work of Couinaud, who described the segmental anatomy of the liver (Couinaud 1957). The liver is composed of eight segments including the caudate lobe (segment I), three segments (II–IV) of the anatomical left lobe and four segments (V–VIII) of the right lobe (Bismuth 1982) (see Plate 79, Atlas: p. 469). It is possible to use a single-segment liver graft but in practice the liver is usually divided along the plane of the falciform ligament to provide a left lateral segmental graft (segments II and III) drained by

the left hepatic vein. In the reduced graft, the common bile duct, portal vein and hepatic artery are all preserved with the left lateral segment. In contrast, when the liver is split we usually preserve the main trunks of these structures, together with the inferior vena cava, with the right graft. At implantation, microvascular techniques and biliary reconstruction using a Roux loop of jejunum are required for the left split graft.

Liver reduction was first used by Bismuth in Paris and proposed as a potential solution to the severe shortage of small paediatric livers (Bismuth & Houssain 1984). Although initial results were poor, the introduction of University of Wisconsin liver preservation solution (Kalayoglu *et al.* 1988), and technical modifications improved graft survival to match, or even surpass, results with whole livers in small children and infants (Broelsch *et al.* 1990; Busuttill & Goss 1999). In particular, reduced grafts have a lower incidence of hepatic artery thrombosis compared with equivalent-sized whole liver grafts in young children. The technique of liver reduction was modified to enable split-liver grafting, so that a single liver could be used for two recipients (Pichlmayr *et al.* 1988).

Liver reduction/splitting is performed either *in situ* as part of the donor operation or *ex situ* on the back table. *In-situ* liver reduction or splitting has the advantage that the surgery is performed on a well-perfused functioning liver without the risk of warm ischaemia during back table surgery. It also enables meticulous haemostasis at the cut surface. However, *in-situ* division adds about 2 h to the operating time at the donor hospital with the attendant risk of donor instability and, perhaps, compromise to other donor organs. Because of concerns about primary graft dysfunction due to prolonged cold ischaemia, *ex-situ* splitting is usually restricted to livers from stable young donors whereas *in-situ* split grafts may have wider applications (Noujaim *et al.* 2000).

The recipient operation

In the early days of liver transplantation, the operation was frequently complicated by extensive bleeding from raw surfaces, particularly in patients with adhesions from previous upper abdominal surgery. Patients with advanced liver disease have portal hypertension, thrombocytopenia and deranged coagulation. During a long operation in a patient with poor liver function, hypothermia exacerbates the coagulopathy. A better understanding of coagulation disorders, improved monitoring, and more sophisticated haemostatic techniques have greatly reduced transfusion requirements.

Anaesthetic monitoring includes serial measurements of blood gases, electrolytes, haemoglobin and platelet count together with coagulation indices including thromboelastography. The thromboelastograph gives a pictorial representation of blood clotting and its interpretation

allows the anaesthetist to determine whether there is a defect in clotting factors or platelets, or whether antifibrinolytic drugs such as aprotinin are indicated.

In adults and larger children, the use of venovenous bypass, in which blood is diverted from the portal and infrahepatic caval circulation to the superior vena cava, not only reduces portal hypertension and intestinal congestion when the portal vein is clamped, but also improves venous return and renal perfusion when the vena cava is clamped during hepatectomy.

The recipient liver transplant operation is carried out through a bilateral subcostal incision, often with an upper midline extension. The operation can be divided into two phases: total hepatectomy, in which the old liver is dissected and removed; and liver graft implantation.

Total hepatectomy

In the virgin abdomen, hepatectomy is usually straightforward. However, if there has been previous upper abdominal surgery with bleeding, bile leakage or local sepsis, then the dissection may be much more difficult (this is commonly the case following a previous Kasai portoenterostomy for biliary atresia). The liver is mobilized by division of adhesions to surrounding structures. The porta hepatis is dissected and the bile duct (or Kasai porto-enterostomy), hepatic artery and portal vein divided. The liver is then removed by dividing the hepatic veins which drain into the inferior vena cava. Alternatively, the old liver can be removed in continuity with the retrohepatic vena cava. The latter technique is commonly used in cases of liver cancer such as hepatoblastoma in order to ensure complete excision of the tumour.

Graft implantation

Once the liver graft is removed from the cold preservation fluid it starts to warm; the smaller the liver the more rapid the warming. Thus the vascular anastomoses are performed expeditiously in order to minimize warm ischaemic injury. For a whole graft the vena cava, and portal vein are anastomosed to the equivalent recipient vessels, taking care not to constrict the anastomoses when tying the sutures. For a left lateral segment graft, a triangular incision is made on the anterior aspect of the recipient vena cava for anastomosis of the graft left hepatic vein. Following completion of the venous anastomoses the liver is flushed with a warm rinsing solution to remove cold preservation fluid, and the venous clamps removed. Following reperfusion of the liver from the portal vein, the arterial anastomosis is carried out. The site depends upon the anatomy and relative calibres of the donor and recipient arteries. Most commonly the donor coeliac artery is anastomosed to the bifurcation of the recipient hepatic and gastroduodenal or splenic arteries.

In small children and those with aberrant vessels we often employ vascular conduits. A hypoplastic portal vein (commonly associated with biliary atresia) can be replaced with donor iliac vein. Similarly, a donor arterial graft may be needed to act as a conduit from the recipient aorta to the donor hepatic artery.

The final anastomosis is to the graft bile duct. In adults and larger children without previous biliary pathology the donor and recipient common bile ducts are joined together. Children with biliary atresia and those weighing less than 40 kg require a choledochojejunostomy using a Roux-en-Y loop of recipient jejunum. Biliary complications are more common in small children (Chardot *et al.* 1995), partly due to the small calibre of the donor bile duct and partly due to the more tenuous blood supply to the bile duct of a reduced-size liver.

Once the anastomoses have been completed, the operative field is checked for haemostasis and coagulopathy corrected. Bleeding at this stage may originate from raw areas following the hepatectomy, from the surgical suture lines, or from the graft itself. During the first hour after reperfusion there is usually evidence that the liver is working with spontaneous correction of acidosis and clotting factors, and production of bile. In a proportion of cases (up to 25% of small children) the liver graft may be too large to permit abdominal closure without compromising hepatic venous outflow and also ventilation. In such circumstances we usually insert a temporary patch of prosthetic material into the abdominal wall before closing the skin. A large graft will rapidly shrink and the patch can usually be removed after a few days (De Ville de Goyet *et al.* 1998).

Living related liver transplantation

The shortage of suitable donors for small children prompted Broelsch and colleagues (Broelsch *et al.* 1991) to adapt the techniques of split cadaveric liver transplantation to obtain partial liver grafts from living donors. There are several potential advantages of living related transplantation. First, it improves the supply of liver grafts for small children who might otherwise die whilst waiting for a suitable cadaveric organ. Second, live donation allows optimal timing of the transplant as an elective procedure, and reduces the stress of waiting for a suitable organ. Third, the graft is obtained from a healthy individual with minimal preservation time.

Against the benefits to the recipient, however, must be set the potential risks to the donor. Partial hepatectomy, even in a healthy individual, is associated with an appreciable morbidity. There have been reports of several donor deaths; risk of donor mortality is estimated at between 1:100 and 1:250 depending upon whether a larger right liver graft or a smaller left graft is taken (Fujita *et al.* 2000). Donor complications include bile leaks and haem-

orrhage from the cut surface, wound pain, infection and incisional hernia, and a surprisingly high incidence of gastritis and peptic ulceration. Potential donors require careful assessment to ensure that they can provide a graft of suitable size, quality and blood group to the recipient without excessive risk to the donor. Donation must be altruistic without coercion by other family members. All donors should have a formal psychological assessment and be counselled about the perioperative risks and possible long-term complications of the procedure. Preoperative investigations include liver function tests, serology and imaging to assess the size of the intended segmental graft as well as details of its vascular and biliary anatomy. Imaging may indicate abnormal graft parenchyma, in particular fatty change. If in doubt a liver biopsy may be necessary.

For a child, the graft from a live donor is usually a left lateral graft (liver segments II+III). During the donor operation the left branches of the hepatic artery, portal vein and bile duct and the left hepatic vein are identified and the liver parenchyma divided along the line of the falciform ligament. The vascular and biliary structures are then divided and the graft flushed with cold preservation fluid. Implantation is similar to that employed for left lateral segmental cadaver grafts (see above). Microsurgical techniques are required for the arterial anastomosis to reduce the risk of thrombosis. Following the introduction of this technique, excellent results were reported from Japan where there is a severe shortage of cadaver donors (Tanaka *et al.* 1993). In the USA approximately one-third of paediatric liver transplants are now performed from living donors. In the UK an active policy on split liver transplantation has largely obviated the need for live donor transplantation. Clearly, parents considering live donation must be fully informed of the risks of the procedure and the prospects of finding a cadaver graft before making a decision.

Auxiliary liver transplantation

Auxiliary liver transplantation involves transplantation of a donor liver graft without removal of the entire native liver. Its purpose is to retain the native liver in case of spontaneous recovery or for future gene therapy. It is of value in those metabolic liver diseases in which there is a functionally normal liver but transplantation is indicated for severe extrahepatic disease (e.g. Crigler-Najjar type I). In this situation only a small amount of normal liver is needed to compensate for the metabolic defect, and it usually is sufficient to replace the left lateral segments (II and III) with an equivalent donor graft. Reports suggest that this is successful in reducing the levels of unconjugated bilirubin in Crigler-Najjar type I (Rela *et al.* 1997). This operation is not indicated for metabolic liver disease such as primary oxalosis in which the

390 Section 10: Transplantation

enzyme deficiency contributes to an excess of oxalate production, or in metabolic diseases such as Wilson's disease or tyrosinaemia in which there is a risk of malignancy in the retained liver.

Auxiliary liver transplantation may also be considered for patients with fulminant or subfulminant hepatic failure when there is potential for the original liver to recover (Boudjema 2002). This requires a large auxiliary graft, usually replacing a right or an extended right lobe. Survival rates may be less than with conventional transplantation (Sudan *et al.* 1997). It is contraindicated when the liver disease is irreversible (e.g. seronegative hepatitis) but may have a role in reversible toxic injuries such as paracetamol poisoning. Once the native liver has recovered, immunosuppression is gradually withdrawn and the liver graft atrophies due to chronic rejection.

Postoperative management

Ventilation

Although it is possible to extubate some patients in the operating room, it is generally advisable to stabilize the patient in the intensive care unit (ICU) to ensure that liver function is satisfactory with good hepatic artery and portal vein flow on Doppler ultrasound before discontinuing ventilation. Moreover, large upper abdominal incisions are notoriously painful in the early postoperative period, necessitating epidural analgesia, intravenous morphine (according to body weight) or alfentanil (0.5 mg/kg/min), which may depress respiration. Young infants with severe malnutrition due to chronic liver disease or patients in hepatic coma due to fulminant liver failure may spend a prolonged period in ICU, but the majority of patients return to the ward within 24–48 h postoperatively.

Fluid management

The principles of fluid management are to maintain circulating volume by providing two-thirds of maintenance fluids with crystalloid, while half-replacing wound drain losses with 4.5% albumin as long as urine output is in excess of 1 ml/kg/h and central venous pressure is satisfactory (>5–6 mmHg). Patients are often vasoconstricted and relatively hypovolaemic on return from theatres due to fluid losses, especially if there has been preoperative ascites, hypothermia and the use of intraoperative inotropes. Extra colloid fluid replacement with 4.5% albumin and inotropes, such as dopamine (2–5 mg/kg/min) may be necessary. Haemoglobin should be maintained between 8 and 10 g/l. Excessive blood transfusion is contraindicated as a postoperative haemoglobin of <10 g/l reduces the risk of hepatic artery thrombosis (Buckels *et al.* 1989). Venesection is recommended for any patient with a haemoglobin >11 g/l during the first 2 postoperative weeks.

Immunosuppression

There have been many recent advances in immunosuppressive drugs, but current protocols consist of the calcineurin inhibitors:

- (i) cyclosporin microemulsion (Neoral), prednisolone and azathioprine;
- (ii) tacrolimus combined with prednisolone (Table 20.4).

Steroids are reduced over the first 2 weeks and withdrawn or reduced to alternate day therapy after 3 months to improve growth. Azathioprine is usually discontinued after 1 year. Cyclosporin or tacrolimus are continued for life. Although most immunosuppressant drug monitoring is with trough levels, it is possible that peak

Table 20.4 Postoperative management of liver transplantation.

Fluid management

Maintain: CVP > 6 cmH₂O

Urine output > 1 ml/kg/h with 4.5 or 20% albumin or 5–10% dextrose

Hb < 11 g/l

Prophylactic antibiotics

- 1 Cefuroxime 20 mg/kg/dose t.d.s. for 48 h
- 2 Amoxil 25 mg/kg/dose t.d.s. for 48 h
- 3 Metronidazole 8 mg/kg/dose t.d.s. over 1 h for 48 h (or rectally)
- 4 Nystatin: 50 000 units orally q.d.s. if < 10 kg
100 000 units orally q.d.s. if > 10 kg
- 5 Amphotericin 1 ml/day orally
- 6 If CMV positive donor, acyclovir 500 mg/m²/i.v. dose t.d.s. over 1 h
- 7 Co-trimoxazole < 5 years 240 mg od po; > 5 years 480 mg od po, for 6 months

Antiplatelet therapy

- 1 Aspirin 3 mg/kg/day PR or NG (maximum 75 mg)
- 2 Dipyridamole: if < 10 kg, 25 mg t.d.s. orally for 3 months
if > 10 kg, 50 mg t.d.s. orally

Anticoagulation (if necessary)

Heparin (60–120 units/kg/day) to maintain PT 20–30 s

Antacids

Ranitidine 3 mg/kg/dose t.d.s.

If gastric pH < 5, omeprazole 10–20 mg i.v. b.d.

Antihypertensives

- Acute: 1 Labetalol 1–3 mg/kg/h
2 Nifedipine 5–10 mg/dose s.l. p.r.n.
- Chronic: 1 Nifedipine 5–10 mg t.i.d.
2 Atenolol 25–50 mg/day

Immunosuppression

	Cyclosporin A (ME) 5 mg/kg b.d.	or	Tacrolimus 0.075 mg/kg b.d.
Trough levels:			
0–1 month	200–250 ng/l		8–12
1–3 months	180–200 ng/l		5–8
3–12 months	150–200 ng/l		3–8
> 12 months	70–100 ng/l		3–5
	Prednisolone 2 mg/kg (↓) 3 months		Prednisolone 2 mg/kg (↓) 3 months
	Azathioprine 1–2 mg/kg 12 months		

cyclosporin levels (C2 levels) may be more effective in preventing rejection and reducing side-effects (Keown *et al.* 1998).

A recent European multicentre study, which directly compared tacrolimus with neoral post transplant, demonstrated a significant reduction in the incidence of acute and steroid-resistant rejection in the tacrolimus group compared with the cyclosporin group without significant difference in adverse side-effects (Kelly *et al.* 2002), although long-term outcome is still being evaluated.

Mycophenolate mofetil (MMF) 10–40 mg/kg has recently been developed as an adjuvant immunosuppressive agent. It is an antiproliferative agent which is similar in action to azathioprine and may depress the bone marrow. The long-term safety and efficacy is undetermined but it has no cosmetic side-effects, is renal sparing and does not require drug monitoring. It was initially used as rescue therapy and was found to be effective and safe but with significant gastrointestinal and haematological side-effects in adults. More recently MMF has been used with neoral and prednisolone as primary immunosuppression (Renz *et al.* 1999; Chardot *et al.* 2001).

Anti-interleukin-2 receptor antibodies (IL-2 antibodies) are monoclonal antibodies, which selectively target the IL-2 receptors on activated T-cells, which is a key step in the development of cell-mediated immunity. Two antibodies are available, Basiliximab and Daclizumab, both of which are renal sparing and provide effective induction immunosuppression post transplant in combination with a calcineurin inhibitor in adults. To date there is little experience with children (Ganschow *et al.* 2001; Kelly 2001).

Sirolimus is a macrocyclic triene antibiotic which prevents T-cell proliferation by inhibiting cytokine production and does not inhibit calcineurin. In adults, sirolimus has been evaluated as both primary and rescue immunosuppression for liver transplant recipients and has the advantage of being both renal sparing and reducing the need for high-dose steroids (McAlister *et al.* 2001). Significant side-effects include delayed wound healing, hyperlipidaemia and an increase in the rate of hepatic artery thrombosis, and it should not be used immediately post transplant but may be useful for chronic rejection. There are few studies of sirolimus in paediatric liver transplantation, although conversion to sirolimus was effective in children who developed hypertrophic obstructive cardiomyopathy on tacrolimus (Pappas *et al.* 2000).

Prophylactic antibiotics

Broad-spectrum antibiotics are prescribed for 48 h unless there is continuing infection (Table 20.4). Systemic antifungals, fluconazole or liposomal amphotericin, should

be continued for 14 days in children with acute liver failure or those undergoing a second laparotomy for complications (Tollema *et al.* 1995). Whilst patients are on steroids it is advisable to give low-dose cotrimoxazole or trimethoprim as prophylaxis against *Pneumocystis carinii* infection. Oral nystatin and amphotericin to prevent oral and oesophageal candidiasis may be continued for 6–12 months.

Prophylaxis for CMV infection is required for CMV-negative recipients of a CMV-positive donor. Acyclovir (1500 mg/m²/day i.v. or 200–400 mg/dose q.d.s. orally) or ganciclovir (5 mg/kg) prevents infection in the short term when immunosuppression is intense (Davison *et al.* 1993). There is no satisfactory prophylaxis for EBV, although some units use acyclovir or ganciclovir.

Other medications

The incidence of stress ulcers and excess gastric secretion is high in children recovering from liver transplantation, particularly those on high doses of steroids (Dimand *et al.* 1989; Kelly 1994a). Therefore, it is important to prevent steroid-induced peptic ulceration with ranitidine, which, unlike cimetidine, does not interact with cyclosporin sucralfate (2–4 g q.d.s.) and/or omeprazole (10–20 mg i.v. b.d.).

Antiplatelet drugs, aspirin and dipyridamole are prescribed to prevent vascular thrombosis and discontinued at 3 months. Intravenous heparin and/or warfarin may be indicated for children with a high risk of thrombosis. Antihypertensive medication is usually required because of the effects of the immunosuppressive therapy. Nifedipine (5–10 mg/dose) and/or atenolol (25–50 mg/dose) are usually adequate.

Postoperative complications

Early postoperative complications

Complications in the early postoperative period may be due to:

- the preoperative condition of the recipient (e.g. malnutrition, sepsis, renal failure)
- the quality of the graft (e.g. primary non-function, acidosis, coagulopathy)
- surgical complications (e.g. intra-abdominal haemorrhage, vascular thrombosis, venous outflow obstruction)
- side-effects from drugs (e.g. cyclosporin-induced renal failure; hyperglycaemia from either tacrolimus or cyclosporin).

A number of factors may predispose to postoperative renal failure. Some patients have impaired renal function preoperatively which may have been aggravated by intraoperative cardiovascular instability requiring inotropic support. In such patients early administration of

392 Section 10: Transplantation

nephrotoxic immunosuppression, such as cyclosporin or tacrolimus, should be delayed as rejection is not usually a problem in the first 2–3 days post transplant. Alternatively, renal sparing drugs such as MMF, sirolimus or IL-2 antibodies should be considered. Oliguria is common and should be managed by ensuring adequate fluid replacement or frusemide challenge (1–2 mg/kg i.v., or infusion 0.25 mg/kg/h). Anuria with a rising urea, creatinine or potassium requires renal haemodialysis or filtration.

The main causes of graft loss in the first week include:

- primary non-function (PNF) secondary to hyperacute rejection which occurs on day 4–5
- hepatic artery or portal vein thrombosis
- systemic sepsis.

Primary non-function is a serious complication which requires immediate retransplantation. It may be suspected if there is persistent coagulopathy, acidosis, a high potassium and transaminases >10000 IU/l. If secondary to hyperacute rejection, the diagnosis can only be made by liver biopsy (which may be impractical) or by identification of raised immunoglobulins (Adams *et al.* 1990). Treatment consists of retransplantation or an increase in immunosuppression.

Hepatic artery thrombosis occurs in 10% of children. The incidence has fallen following the introduction of reduction hepatectomy and split liver grafts with the use of larger donor blood vessels (Rela *et al.* 1996; Mirza *et al.* 1998). Medical prevention of hepatic artery thrombosis is by maintaining a low haematocrit (<10 g/haemoglobin) and the use of antiplatelet agents such as aspirin (3 mg/kg/day) and dipyridamole (25–50 mg t.d.s.) (Buckels *et al.* 1989). Portal vein thrombosis is less common. The diagnosis of hepatic artery or portal vein thrombosis is made by Doppler ultrasound and confirmed by angiography (see Plate 80, Atlas: p. 469). Treatment includes:

- immediate laparotomy with thrombectomy and use of anticoagulants
- retransplantation.

Retransplantation is not always required as collateral blood vessels may develop. Late complications of hepatic artery thrombosis include biliary leaks and strictures or hepatic abscesses (Chardot *et al.* 1995).

Systemic sepsis is treated as indicated with broad-spectrum antibiotics and antifungals. Retransplantation is not indicated if sepsis leads to multiorgan failure and graft non-function.

Haemorrhage from the cut surface of the liver is a rare complication and is managed conservatively unless there is confirmed bleeding or haemodynamic instability. Abdominal tamponade may decrease renal blood flow causing renal failure.

Complications after the first postoperative week

Complications arising after the first postoperative week include:

- acute rejection
- biliary leaks/strictures
- persistent wound drainage
- sepsis.

Acute rejection is less common in infants (20%) but increases to 50–60% in older children (Murphy *et al.* 1996). The clinical signs and symptoms include fever, irritability and abdominal discomfort. The diagnosis is confirmed by detecting a rise in bilirubin, alkaline phosphatase, aspartate and alanine transaminases, and γ -glutamyl transpeptidase (GGT). It is always necessary to have histological confirmation. Acute rejection is indicated by a mixed inflammatory infiltrate in portal tracts with sub-endothelial lymphoid infiltration (endothelialitis) and inflammatory infiltration of bile ducts (Hubscher 1996) (see Plate 81, Atlas: p. 469). Treatment is with pulse methylprednisolone (20–40 mg/kg/day) intravenously over 2 or 3 days. If there is inadequate histological or biochemical response, treatment with methylprednisolone may be repeated but conversion to a more potent immunosuppressive drug such as tacrolimus may be required (Reyes *et al.* 2000).

Chronic rejection occurs in <10% of children at any time post transplant (Murphy *et al.* 1996). The diagnosis is suggested by the gradual onset of jaundice, pruritus and pale stools which indicate biliary obstruction. Biochemical changes include a higher rise in bilirubin, alkaline phosphatase and GGT than in transaminases. Histology may demonstrate extensive damage and loss of bile ducts (vanishing bile duct syndrome) with arterial obliteration and fibrosis (see Plate 82, Atlas: p. 469). Most children respond to an increase in immunosuppression, such as the addition of MMF or conversion to tacrolimus or sirolimus, but some require retransplantation.

The incidence of biliary complications has increased with the use of reduction hepatectomies and split liver grafts (Chardot *et al.* 1995; Mirza *et al.* 1998). Biliary strictures may be secondary to an anastomotic stricture, oedema of the bile ducts or hepatic artery ischaemia. Biliary leaks may be secondary to leakage from the cut surface of the liver or from hepatic artery ischaemia. Most biliary leaks will settle with conservative management. Large leaks causing biliary peritonitis, biliary abscesses or sepsis will require surgical drainage and reconstruction. The majority of intrahepatic biliary strictures are now managed medically with ursodeoxycholic acid or radiologically using percutaneous transhepatic cholangiography. The dilated biliary tree is cannulated and external biliary drainage established (see Plate 83a,b, Atlas: p. 470). Biliary dilatation may be performed using balloons and biliary stents. Surgical reconstruction is now only required

for the management of extrahepatic biliary strictures or if interventional radiology fails.

Persistent drain losses may be due to preoperative ascites or secondary to rejection, sepsis, hepatic vein obstruction or peritonitis. It may lead to acidosis and coagulopathy due to loss of bicarbonate and coagulation factors. Treatment is of the primary cause, fluid restriction and diuretics.

Sepsis is still the commonest complication following liver transplantation (60–70%) (Beath *et al.* 1993a). The majority of infections are bacterial infections related to central line insertion (*Streptococcus faecalis* and *S. viridans*, *Pseudomonas aeruginosa* and *Staphylococcus aureus*). Fungal infections with *Candida albicans* and *Aspergillus* spp. are documented in approximately 20% of patients and are particularly common in patients with fulminant hepatitis with acute hepatic necrosis pretransplant. Vancomycin-resistant enterococcus (VRE) is a common gut pathogen, but systemic infection requires treatment with Synercid (Gray *et al.* 2000).

Late complications post-liver transplant

Late complications (after 3 weeks) may occur at any time post transplant. They include:

- side-effects of immunosuppression
- CMV or EBV infection
- post-transplant lymphoproliferative disease (PTLD)
- late biliary stricture
- late hepatic artery or portal vein thrombosis.

There are numerous side-effects of immunosuppressive therapy (Table 20.5). Some are short term, such as stunting and hypertension secondary to steroids, while nephrotoxicity and increased risk of viral infection are lifelong. Hirsutism and gingival hyperplasia are side-effects of cyclosporin which, although cosmetic, have an

important effect on quality of life. With careful monitoring of immunosuppression to ensure adequate trough levels, nephrotoxicity should be minimized (Ellis *et al.* 1986; Bartosh *et al.* 1997).

CMV infection occurs 5–6 weeks post transplant despite prophylaxis with acyclovir or ganciclovir (Davison *et al.* 1993; Mellon *et al.* 1993; Gane *et al.* 1997). It is more common in children than adults, reflecting the number of CMV-negative children undergoing liver transplantation. The risk of CMV disease as opposed to CMV infection is indirectly related to receiving a transplant from a CMV-positive donor, but is usually treated effectively with high-dose ganciclovir 5 mg/kg and hyperimmune CMV globulin dose.

The development of primary EBV is a significant long-term problem. Approximately 65% of children undergoing liver transplantation will be EBV-negative pretransplant and 75% of this group will have a primary EBV infection within 6 months of transplantation (Davison *et al.* 1993). It is important to diagnose primary EBV infection and reduce immunosuppression, if possible, in order to prevent further progression to lymphoproliferative disease (Newell *et al.* 1996).

There is a close relationship between primary EBV infection and the development of lymphoproliferative disease (Ho *et al.* 1988). The spectrum of B-lymphocyte proliferation ranges from benign hyperplasia to malignant lymphoma. The clinical features may represent infectious mononucleosis, isolated lymphoid involvement or malignant lymphoma EBV. Polymerase chain reaction (PCR) is usually positive, but is not diagnostic of PLTD. The diagnosis is based on identifying the characteristic histology from the affected tissue, which may demonstrate polymorphic B-cell proliferation or lymphomatous features of nuclear atypia and necrosis. EBER staining for EBV is positive. Immunofluorescent staining of heavy-chain and light-chain immunoglobulins may differentiate monoclonal from polyclonal infiltrates. Almost any organ in the body may be affected, although the liver and gut are most commonly involved. Although initially it was felt that the incidence was higher with tacrolimus than with cyclosporin, this may be due to the initial use of inappropriately high levels of tacrolimus (Cox & Freese 1996; Furlan *et al.* 2000).

Treatment includes:

- reduction of immunosuppression
- intravenous acyclovir (3 mg/m²) or ganciclovir (6–10 mg/kg) may be effective (McDiarmid *et al.* 2002)
- infusion of autologous T-cells directed against EBV cells (Haque *et al.* 2002) is a research technique which may have future potential
- chemotherapy which is tailored to the type of lymphoma is necessary if the lymphoproliferative disease becomes overtly malignant, chemotherapy is required if the PTLD becomes overtly malignant

Table 20.5 Immunosuppressive complications post transplantation.

Drug	Complications
Steroids	Stunting Hypertension Cushingoid facies
Cyclosporin A	Hirsutism Gingival hyperplasia Hyperlipidaemia
CYA/Tacrolimus	Nephritis Hypertension Neurotoxicity Hyperglycemia ?Lymphoproliferative disease
Tacrolimus	?Cardiomyopathy

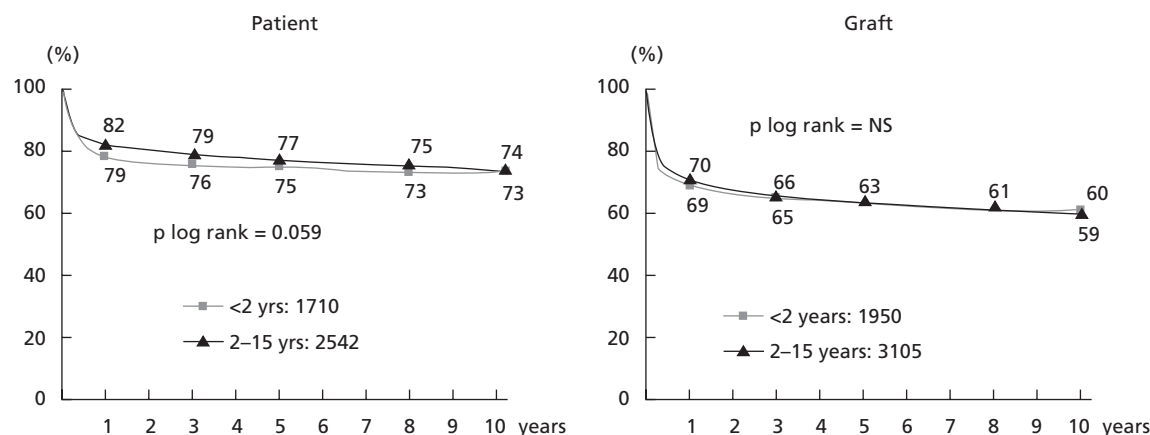


Fig. 20.2 Survival post-liver transplantation according to recipient age 1988–2001 (European Liver Transplant Registry).

- if the reduction in immunosuppression leads to rejection, then balancing therapy is difficult.

Late biliary strictures are usually due to hepatic artery thrombosis and lead to cholangitis and biliary cirrhosis. They are treated radiologically as above (see Plate 83, Atlas; p. 470) or by surgery.

Late hepatic thrombosis does not usually require treatment as collateral blood supply becomes established. Portal vein stenosis, due to an anastomotic stricture, may lead to portal hypertension and should be treated radiologically by venoplasty or surgical reconstruction or shunt (see Plate 84, Atlas; p. 470).

Survival following liver transplantation

Current results from international units indicate that 1-year survival after paediatric liver transplantation may be as high as 90% (Beath *et al.* 1993a; Cacciarelli *et al.* 1997; McDiarmid *et al.* 2002; European Liver Transplant Registry 2002). Long-term survival (5–8 years) ranges from 60 to 80% (Eckhoff *et al.* 1994; Yandza *et al.* 1994; Belle *et al.* 1995; Andrews *et al.* 1996; Sudan *et al.* 1998) (Table 20.6). Patients receiving elective living related liver transplantation may have a higher 1-year survival (94%) compared with those receiving cadaveric grafts (78%) (Kuang *et al.* 1996; Hashikura *et al.* 2001).

Factors affecting survival

There are a number of factors which may influence survival. Age at transplantation has previously been considered a significant risk factor and transplantation was originally contraindicated in infants under 1 year old (Zitelli *et al.* 1987). The technical developments which have included reduction hepatectomy, split liver transplantation and living related transplantation have reduced waiting list mortality (Ryckman *et al.* 1991) and

Table 20.6 Current long-term survival of liver transplantation in children.

Centre	n	Actuarial survival in years		
		1	2–5	10
Brussels	261	–	78%	–
Birmingham	356	78.5%	75%	–
Nebraska	212	–	–	83.7%
Dallas	202	76%	70%	–
Brisbane	153	82%	74%	70%
Groningen	66	86%	70%	73%
Wisconsin	76	84%	77.3%	–

*Eight-year actuarial survival.

extended liver transplantation to this young age group (Beath *et al.* 1993a; Millis *et al.* 2000), even in infants less than 5 kg (Noujaim *et al.* 2001).

Many studies have indicated that the inevitable protein malnutrition which affects children with end-stage liver disease had a significant influence on morbidity and mortality post-liver transplantation. Chin *et al.* (1991) found a significant difference in the 2-year actuarial survival for children with standard deviation scores (SDS for weight) < –1 (57%) compared with those > –1 (95%). This was confirmed using height standard deviation scores in which children who are less stunted at the time of their operation had an improved outcome, indicating the necessity for preoperative nutritional support (Moukarzel *et al.* 1990) (Chapter 14).

The severity of liver disease has a significant effect on short-term survival as children transplanted electively have an improved survival compared with those transplanted for acute liver failure or fulminant hepatitis (Belle *et al.* 1995; Rodeck *et al.* 1996).

Recurrent disease post transplantation

In some instances survival may be affected by the recur-

rence of the original disease. Recurrence of hepatitis B virus (HBV infection) is almost 100% likely in those children who are HBV DNA-positive or HBe antigen-positive at the time of their operation (O'Grady *et al.* 1992). Recurrent HBV disease is associated with a chronic hepatitis or cirrhosis (79%), submassive necrosis (9%) or fibrosing cholestatic hepatitis, which is a fatal form of fulminant hepatic failure (25%) (Davies *et al.* 1991; Lucey *et al.* 1992). Prophylaxis with anti-HBV human immunoglobulin (HBIG) was replaced with the nucleoside analogue, lamivudine, which effectively prevented recurrence, but at the expense of the emergence of lamivudine-resistant YMDD mutants (Mutimer 1999). It is possible that adefovir prophylaxis may be more effective as YMDD mutants do not develop. Recurrence of hepatitis B infection in children transplanted for fulminant hepatitis B is unusual.

Although chronic hepatitis C is an unusual indication for liver transplantation in childhood, a number of children were infected preoperatively before screening became available (Chapter 8) (Nowicki *et al.* 1994; Pastore *et al.* 1995). Reinfection of the graft is inevitable, but some adults have responded to postoperative treatment with the combination of Interferon and Ribavirin (Mutimer 1999).

Recent studies have indicated that autoimmune hepatitis may recur both immunologically and histologically, and may be more severe than the original disease (Birnbaum *et al.* 1997). Giant-cell hepatitis in association with autoimmune haemolytic anaemia is a rare disease which has been shown to recur post transplant (Horsmans *et al.* 1995). The outcome for children transplanted for malignant hepatic tumours is related to the rate of recurrence, and if no extrahepatic metastases were present at the time of surgery long-term outcome may be excellent (Achilleos *et al.* 1996).

De novo autoimmune hepatitis

A number of recent studies have documented the development of autoantibodies (ANA, SMA and rarely LKM) post transplant in both children and adults in recipients who did not have autoimmune disease pretransplant (Kerkar *et al.* 1998; Andries *et al.* 2001). The incidence varies from 2% to 3% to 50% with time and is associated with a graft hepatitis and progressive fibrosis (Evans *et al.* 2001). Although the aetiology is unknown, the hepatitis resolves with steroid therapy, or with azathioprine (Salcedo *et al.* 2002).

Longterm renal function

The development of nephrotoxicity with both cyclosporin and tacrolimus is inevitable, although only 4–5% of patients develop severe chronic renal failure long

term requiring renal transplantation. The use of low dose calcineurin inhibitors or renal sparing drugs such as mycophenolate mofetil or sirolimus for maintenance immunosuppression prevents significant renal dysfunction (Arora *et al.* 2000; Berg *et al.* 2001; Evans *et al.* 2001). Acute postoperative hypertension is seen in 65% of children, but only persists in 28% (Bartosh *et al.* 1997).

Hyperlipidaemia

Cyclosporin and sirolimus both increase serum lipids, particularly cholesterol, which resolves on transfer to tacrolimus or mycophenolate (Reyes *et al.* 2000).

Transplant tolerance

There is considerable interest in the development of transplant tolerance, and adult studies have demonstrated that approximately 20% of patients can be withdrawn from immunosuppression (Riordan & Williams 1999). Complete withdrawal of immunosuppression in children is anecdotal and related to case reports of anergy following post-transplant lymphoproliferative disease. Children may be more likely to become tolerant post transplant, because they require less immunosuppression and are less likely to develop rejection than older children and adults, perhaps because neonates have a greater TH2 (T helper) response than adults, which is more likely to lead to graft acceptance (Ganschow *et al.* 2001).

Quality of life post transplant

Children who survive the initial 3 months post transplant without major complications should achieve a normal lifestyle despite the necessity for continuous monitoring of immunosuppressive treatment. Children who underwent transplant for metabolic liver disease have both phenotypic and functional recovery (α_1 -antitrypsin deficiency, Wilson's disease and tyrosinaemia type I). Children with organic acidaemias will only have palliation of their defect if the enzyme defect is not restricted to the liver (propionic acidaemia or methylmalonic acidaemia) (Kelly 1994b; Gissen *et al.* 2001).

Growth post transplant

Early studies evaluating growth in children post-liver transplantation indicated that up to 59% of children did not achieve catch-up growth (Andrews *et al.* 1989). In contrast, more recent studies have indicated that approximately 80% of survivors will achieve normal growth patterns and body habitus (Chin *et al.* 1991; Rodeck *et al.* 1994; Holt *et al.* 1997; Viner *et al.* 1999).

396 Section 10: Transplantation

In the majority of children who have had a successful liver transplant there is a rapid return to normal of mid-arm muscle area and mid-arm fat area within 6–12 months post transplant (Beath *et al.* 1993b). Weight gain may initially be excessive due to the effects of steroids, appetite, and salt and water retention. Most children will regain normal weight within 12 months. Linear growth may be delayed for between 6 and 24 months, which is directly related to steroid dosage and preoperative stunting (McKiernan *et al.* 1992; Codoner-Franch *et al.* 1994; Rodeck *et al.* 1994).

Growth failure post transplant

The most important factors inhibiting growth post transplant are:

- excessive use of steroids
- preoperative stunting
- genetic disorders
- behavioural feeding problems.

Children who are particularly stunted pretransplant (height SDS < -1) initially have rapid catch-up growth but do not achieve their genetic potential, while children who are less stunted (height SDS > -1) have slower catch-up growth but will eventually achieve normal height (McKiernan *et al.* 1992; Sarna *et al.* 1995).

The growth-suppressant effects of corticosteroids in liver transplantation have been documented by many units. Catch-up growth will be observed either when alternate-day steroids are instituted or steroids are discontinued post transplant as is routine in some units (Andrews *et al.* 1994; Dunn *et al.* 1994).

Failure to thrive and stunting are intrinsic features of certain genetic disorders such as Alagille's syndrome. Linear growth may improve post transplantation for Alagille's syndrome, but approximately half these children do not achieve normal height (Cardona *et al.* 1995).

Behavioural feeding problems

Children with end-stage liver disease have associated anorexia and vomiting. They are often fed unpalatable feeds, sometimes by nasogastric tube. Many of these infants may never have fed normally prior to their transplant and thus will have missed their developmental milestones for chewing, swallowing and normal feeding behaviour. The perioperative emphasis on nutritional support often creates parental anxiety about feeding which further exacerbates these difficult behavioural problems. Review of data in Birmingham from our unit shows that up to 60% of patients who were tube-fed prior to liver transplantation develop significant feeding problems postoperatively. The management of these disorders includes a multidisciplinary approach with a dietician, food psychologist and a strict behavioural

feeding regimen. In the minority of patients, however, nocturnal enteral feeding may be required for 1–2 years to maintain normal growth (Kelly 1997).

Psychosocial development

There is an initial deterioration in psychosocial development post transplant as noted by deterioration in social skills, language development, and eye/hand coordination for up to 1 year post transplant (Beath *et al.* 1995; Wayman *et al.* 1997).

However, the majority of children will achieve normal psychosocial development post transplant but the rate of improvement is related to the age of onset of liver disease and age at the time of transplant (Stewart *et al.* 1989). Children who do not have a transplant until significant motor or psychological developmental delay has taken place are unlikely adequately to catch up post transplant and achieve normal developmental scores. In contrast, children who have undergone transplant earlier have been shown to have complete nutritional and developmental catch-up within 1–4 years post transplant and be capable of attending normal school (Beath *et al.* 1995; Stone *et al.* 1997; van Mourik *et al.* 2000) (see also Chapter 1).

It is clear, therefore, that referral for transplantation before children develop irreversible psychosocial developmental delay is mandatory.

Non-compliance with therapy

Non-compliance with immunosuppressive therapy is less common in liver transplant recipients than in renal transplant recipients (Molmenti *et al.* 1999; Watson 2000). This may be because the median age at renal transplantation is 14.3 years, compared with 2.5 years for liver transplantation. It is possible that children who were grafted at a young age are more likely to accept medication through their adolescence (see also Chapter 1).

Endocrine development

Long-term studies from France have shown that children surviving liver transplantation will enter puberty normally, girls will develop menarche and both boys and girls will have pubertal growth spurts (Codoner-Franch *et al.* 1994). Successful pregnancies have been reported (Laifer & Guido 1995; Jain *et al.* 1997).

Family functioning

Few data are available on family functioning but a number of early studies have indicated that the extreme stress experienced by families may lead to marital break-up and dysfunctional family behaviour (Rodrigue *et al.* 1996).

Out-patient monitoring

Initial post-transplant management includes frequent follow-up by the transplant centre, usually at weekly intervals, extending with time to monthly, 3-monthly, and then 6-monthly intervals.

Monitoring should include:

- 1 Assessment of nutritional status by measuring height, weight, triceps skin fold, mid-arm circumference and mid-arm muscle area.
- 2 Detection of potential complications (e.g. rejection, hepatic artery thrombosis, biliary complications) by performing regular liver function tests and 6-monthly or annual abdominal ultrasound examinations.
- 3 Monitoring of immunosuppression to maintain adequate peak or trough levels of cyclosporin and trough levels of tacrolimus to prevent rejection and reduce toxicity (Table 20.4).
- 4 Monitoring for PTLD by EBV PCR 3–6 monthly; and measuring serum albumin as a falling albumin may be an early sign of gut PTLD.
- 5 Protocol liver biopsies. Although annual liver biopsies produce little additional information unless other investigations are abnormal (Rosenthal *et al.* 1997), 5- and 10-year biopsies may detect chronic hepatitis and fibrosis in 25–50% of children which is not related to hepatitis C or G, but may be autoimmune in origin (Davison *et al.* 1998; Evans *et al.* 2001).

It is essential to encourage both child and family to return to a normal life by reducing outpatient visits and encouraging return to school, nursery and playgroup, and discouraging the parents from continuing to maintain their child in a sick role. Many families may find the transition from intensive management in specialist units to the more relaxed outpatient follow-up difficult to cope with, and need additional support and encouragement to regain a normal life.

Promising lines of research

For the moment, liver transplantation is here to stay, although the rapid development of techniques to improve hepatocyte transplantation for acute liver failure or metabolic liver disease is encouraging (Vons 2001; Boudjema *et al.* 2002). The continued advance in targeted immunosuppressive drugs can only improve the outcome for children undergoing liver transplantation (Vincenti 2002).

References

- Achilleos, Q.A., Buist, L.J., Kelly, D.A., McMaster, P., Mayer, A.D. & Buckels, J.A.C. (1996) Unresectable hepatic tumours in childhood and the role of liver transplantation. *Journal of Pediatric Surgery* **11**, 1563–1567.
- Adams, D.H., Hubscher, S.G., Burnett, D. & Elias, E. (1990) Immunoglobulins in liver allograft rejection: evidence for deposition and secretion within the liver. *Transplantation Proceedings* **22**, 1834–1835.
- Andrews, W.S., Shimaoka, S., Sommerauer, J., Moore, P. & Hudkins, P. (1994) Steroid withdrawal after pediatric liver transplantation. *Transplantation Proceedings* **26**, 159–160.
- Andrews, W., Sommerauer, J., Roden, J., Andersen, J., Conlin, C. & Moore, P. (1996) 10 years of paediatric liver transplantation. *Journal of Pediatric Surgery* **31**, 619–624.
- Andrews, W.S., Wanek, E., Fyock, B., Gray, S. & Benser, M. (1989) Pediatric liver transplantation: a 3-year experience. *Journal of Pediatric Surgery* **24**, 77–82.
- Andries, A., Casamayou, L., Sempoux, C., Burlet, M., Raymond, R., Otte, J.B. *et al.* (2001) Post-transplant immune hepatitis in paediatric liver transplant recipients: Incidence and maintenance therapy with azathioprine. *Transplantation* **72**, 267–272.
- Araya, V., Rakela, J. & Wright, T. (1997) Hepatitis C after orthotopic liver transplantation. *Gastroenterology* **112**, 575–582.
- Arora, N., Bunn, S. & McKiernan, P., Beath, S., de Ville de Goyet, J., Kelly, D. (2000) Long term evaluation of renal function after paediatric liver transplantation. *Hepatology* **32**, 341A.
- Bain, V.G., Kneteman, N.M., Ma, M.M. *et al.* (1996) Efficacy of lamivudine in chronic hepatitis B patients with active viral replication and decompensated cirrhosis undergoing liver transplantation. *Transplantation* **62**, 1456–1462.
- Bartosh, S.M., Alonso, E.M. & Whittington, P.F. (1997) Renal outcomes in pediatric liver transplantation. *Clinical Transplantation* **11**, 354–360.
- Beath, S.V., Brook, G.A., Cash, A.J. & Kelly, D.A. (1995) Quality of life after paediatric liver transplantation. *Liver Transplantation and Surgery* **6**, 429.
- Beath, S.V., Brook, G.D., Kelly, D.A. *et al.* (1993a) Successful liver transplantation in babies under 1 year. *British Medical Journal* **307**, 825–828.
- Beath, S., Kelly, D.A. & Booth, I. (1993b) Nutritional support in children with liver disease. *Archives of Disease in Childhood* **69**, 545–549.
- Belle, S.H., Beringer, K.C. & Detre, K.M. (1995) An update on liver transplantation in the United States; recipient characteristics and outcome. *Clinical Transplantation* **10**, 19–33.
- Berg, U.B., Ericzon, B.G. & Nemeth, A. (2001) Renal function before and long after liver transplantation in children. *Transplantation* **27**, 561–562.
- Birnbaum, A.H., Benkov, K.J., Pittman, N.S., McFarlane-Ferrerira, Y., Rosh, J.R. & LeLeiko, N.S. (1997) Recurrence of autoimmune hepatitis in children after liver transplantation. *Journal of Pediatric Gastroenterology and Nutrition* **25**, 20–25.
- Bismuth, H. (1982) Surgical anatomy and anatomical surgery of the liver. *World Journal of Surgery* **6**, 3–9.
- Bismuth, H. & Houssain, D. (1984) Reduced size orthotopic liver grafts in hepatic transplantation in children. *Surgery* **95**, 367–370.
- Bonatti, H., Muiesan, P., Connolly, S. *et al.* (1997) Liver transplantation for acute liver failure in children under 1 year of age. *Transplantation Proceedings* **29**, 434–435.
- Boudjema, K., Bachellier, P., Wolf, P., Tempe, J.D., Jaeck, D. (2002) Auxiliary liver transplantation and bioartificial bridging procedures in treatment of acute liver failure. *World Journal of Surgery* **26**, 264–274.
- Broelsch, C.E., Whittington, P.F. & Emond, J.C. (1990) Evolution

398 Section 10: Transplantation

- and future perspectives for reduced-size hepatic transplantation. *Surgery, Gynaecology and Obstetrics* **171**, 353–360.
- Broelsch, C.E., Whittington, P.F., Emond, J.C. *et al.* (1991) Liver transplantation in children from living related donors. *Annals of Surgery* **214**, 428–437.
- Buckels, J.A.C., Tisone, G., Gunsen, B.K. & McMaster, P. (1989) Low haematocrit reduces hepatic artery thrombosis after liver transplantation. *Transplantation Proceedings* **21**, 2460–2461.
- Burdelski, M., Rodeck, B., Latta, A. *et al.* (1991) Treatment of inherited metabolic disorders by liver transplantation. *Journal of Inherited Metabolic Disease* **14**, 604–618.
- Busuttill, R.W. & Goss, J.A. (1999) Split liver transplantation. *Annals of Surgery* **229**, 313–321.
- Cacciarelli, T.V., Esquivel, C.O., Moore, D.H. *et al.* (1997) Factors affecting survival after orthotopic liver transplantation in infants. *Transplantation* **64**, 242–248.
- Cardona, A., Houssin, D., Gauthier, F. *et al.* (1995) Liver transplantation in children with Alagille syndrome—a study of 12 cases. *Transplantation* **60**, 339–342.
- Chardot, C., Candinas, D., Mirza, D. *et al.* (1995) Biliary complications after paediatric liver transplantation: Birmingham's experience. *Transplant International* **8**, 133–140.
- Chardot, C., Nicoluzzi, J.E., Janssen, M. *et al.* (2001) Use of Mycophenolate mofetil as rescue therapy after paediatric liver transplantation. *Transplantation* **71**, 224–229.
- Chin, S.E., Shepherd, R.W. & Cleghorn, G.J. (1991) Survival, growth and quality of life in children after orthotopic liver transplantation: a 5 year experience. *Journal of Paediatrics and Child Health* **27**, 380–385.
- Codoner-Franch, P., Bernard, O. & Alvarez, F. (1994) Long-term follow-up of growth in height after successful liver transplantation. *Journal of Pediatrics* **124**, 368–373.
- Couetil, J.P., Soubrane, O., Houssain, D.P. *et al.* (1997) Combined heart-lung-liver, double lung-liver, and isolated liver transplantation for cystic fibrosis in children. *Transplant International* **10**, 33–39.
- Couinaud, C. (1957) *Le Foie Études Anatomiques et Chirurgicale*. Masson, Paris.
- Cox, K.L. & Freese, D.K. (1996) Tacrolimus (FK506), the pros and cons of its use as an immunosuppressant in paediatric liver transplantation. *Clinical Investigations in Medicine* **19**, 389–392.
- Davies, S.E., Portman, B.C., O'Grady, J.G. *et al.* (1991) Hepatic histological findings after transplantation for chronic hepatitis B virus infection, including a unique pattern of fibrosing cholestatic hepatitis. *Hepatology* **13**, 150–157.
- Davison, S.M., Murphy, M.S., Adeodu, O.O. & Kelly, D.A. (1993) Impact of cytomegalovirus and Epstein-Barr virus infection in children following liver transplantation. *Gut* **34**, S32.
- Davison, S.E., Skidmore, S.J., Collingham, K.E., Irving, W.L., Hubscher, S.G. & Kelly, D.A. (1998) Chronic hepatitis in children after liver transplantation: role of hepatitis C virus and hepatitis G virus infections. *Journal of Hepatology* **28**, 764–770.
- De Ville de Goyet, J., Hausleithner, V., Reding, R., Lerut, J., Janssen, M. & Otte, J.B. (1993) Impact of innovative techniques on the waiting list and results in paediatric liver transplantation. *Transplantation* **56**, 1130–1136.
- De Ville de Goyet, J., Struye de Swielande, Y., Reding, R. *et al.* (1998) Delayed primary closure of the abdominal wall after cadaveric and living related donor liver graft transplantation in children: a safe and useful technique. *Transplant International* **11**, 117–122.
- Debray, D., Lykavieris, P., Gauthier, F. *et al.* (1999) Outcome of cystic fibrosis-associated liver cirrhosis: management of portal hypertension. *Journal of Hepatology* **31**, 77–83.
- Dimand, E.J., Burchkart, G., Concepcion, W., Hall, R.H. & Starzl, T.E. (1989) Pharmacodynamics of continuous infusion ranitidine in postoperative pediatric liver transplant patients: intragastric pH, bleeding and metabolic alkalosis. *Gastroenterology* **96**, A125.
- Dionsi-Vici, C., Boglino, C., Marcellini, M. *et al.* (1997) Tyrosinaemia Type I with early metastatic hepatocellular carcinoma: combined treatment with NTBC, chemotherapy and surgical mass removal. *Journal of Metabolic Disease* **20**, 3.
- Dunn, S.P., Falkenstein, K., Lawrence, J.P. *et al.* (1994) Monotherapy with cyclosporine for chronic immunosuppression in pediatric liver transplant recipients. *Transplantation* **57**, 544–547.
- Eckhoff, D.E., D'Alessandro, A.M., Knechtle, S.J. *et al.* (1994) 100 consecutive liver transplants in infants and children: an 8 year experience. *Journal of Pediatric Surgery* **29**, 1135–1139.
- Ellis, D., Avner, E. & Starzl, T.E. (1986) Renal failure in children with hepatic failure undergoing liver transplantation. *Journal of Pediatrics* **108**, 393–398.
- Ellis, S.R., Hulton, S.A., McKiernan, P.J., de Ville de Goyet, J. & Kelly, D. (2001) Combined liver kidney transplantation for primary hyperoxaluria type I in young children. *Nephrology, Dialysis, Transplantation* **16**, 348–354.
- European Liver Transplant Registry. (2002) www.eltr.org
- Evans, H.M., McKiernan, P.J. & Beath, S.V., de Ville de Goyet, J., Kelly, D.A. (2001) Histology of liver allografts following paediatric liver transplantation. *Journal of Pediatric Gastroenterology and Nutrition* **32**, 383.
- Filipponi, F., Soubrane, O., Labrousse, F. *et al.* (1994) Liver transplantation for end stage liver disease associated with alpha-1-antitrypsin deficiency in children. Pre-transplant natural history, timing and results of transplantation. *Journal of Hepatology* **20**, 72–78.
- Flynn, D., Mohan, N., McKiernan, P.J. *et al.* (2003) Progress in therapy and outcome for children with neonatal hamochromatosis. *Archives of Disease in Childhood* **88**, F124–F127.
- Francavilla, R., Castellaneta, S.P., Hadzic, N. *et al.* (2000) Prognosis of alpha-1-antitrypsin deficiency-related liver disease in the era of paediatric liver transplantation. *Journal of Hepatology* **32**, 986–992.
- Friedman, A.L., Maller, E., Piccoli, D., Plona, L., Hoftman, M.A. & Lou, A.T. (1994) Encouraging experience with aggressive liver transplantation for children with fulminant hepatic failure at a single transplant center. *Transplantation Proceedings* **26**, 65–66.
- Fujita, S., Kim, I.D., Uryuhara, K. *et al.* (2000) Hepatic grafts from live donors: donor morbidity for 470 cases of live donation. *Transplant International* **13**, 333–339.
- Furlan, V., Debray, D., Fourre, C. & Taburet, A.M. (2000) Conversion from cyclosporin A to tacrolimus in paediatric liver transplantation. *Pediatric Transplantation* **4**, 207–210.
- Gane, E., Saliba, F., Valdecasas, G.J.C. *et al.* (1997) Randomised trial of efficacy and safety of oral ganciclovir in the prevention of cytomegalovirus disease in liver-transplant recipients. *Lancet* **350**, 1729–1733.

- Ganschow, R., Broering, D.C., Nolkempter, D. *et al.* (2001) Th2 cytokine profile in infants predisposes to improved graft acceptance after liver transplantation. *Transplantation* **72**, 929–934.
- Ganschow, R., Broering, D.C., Stuerenburg, I., Rogiers, X., Hellwege, H.H. & Burdelski, M. (2001) First experience with Basiliximab in paediatric liver graft recipients. *Pediatric Transactions* **5**, 353–358.
- Gissen, P., Chakrapani, A., Wraith, J.E. *et al.* (2001) Long-term survival post early liver transplantation in organic acidemias. *Hepatology* **34**, 503A.
- Gray, J., Darbyshire, P.J., Beath, S.V., Kelly, D. & Mann, J.R. (2000) Experience with quinupristin/dalfopristin in treatment infections with vancomycin-resistant *Enterococcus faecium* in children. *Pediatric Infection and Disease Journal* **19**, 234–238.
- Gregorio, G.V., Portmann, B., Reid, F. *et al.* (1997) Autoimmune hepatitis in childhood: a 20 year experience. *Hepatology* **25**, 541–547.
- Grellier, L., Mutimer, D., Ahmed, M. *et al.* (1996) Lamivudine prophylaxis against reinfection in liver transplantation for hepatitis B cirrhosis. *Lancet* **348**, 1212–1215.
- Hadzic, N. (1999) Paediatric sclerosing cholangitis associated with primary immunodeficiency. *Journal of Pediatric Gastroenterology and Nutrition* **28**, 579.
- Haque, T., Wilkie, G.M., Taylor, C., Amlot, P.L., Murad, P., Iley, A. *et al.* (2002) Treatment of Epstein-Barr-virus-positive post-transplantation lymphoproliferative disease with partly HLA-matched allogeneic cytotoxic T cells. *Lancet* **360**, 436–442.
- Hashikura, Y., Kawasaki, S., Terada, M., Ikegami, T., Nakazawa, Y., Urata, K. *et al.* (2001) Long-term results of living-related donor liver graft transplantation: a single-center analysis of 110 transplants. *Transplantation* **72**, 95–99.
- Heyman, M.B. & LaBerge, J.M. (1999) Role of transjugular portosystemic shunt in the treatment of portal hypertension in pediatric patients. *Journal of Pediatric Gastroenterology and Nutrition* **29**, 240–249.
- Ho, M., Jaffe, R., Miller, G. *et al.* (1988) The frequency of Epstein-Barr virus infection and associated lymphoproliferative syndrome after transplantation and its manifestations in children. *Transplantation* **45**, 719–727.
- Hobeika, J., Houssain, D., Bernard, O., DeVictor, D., Grimon, J. & Chapui, Y. (1994) Orthotopic liver transplantation in children with chronic liver disease and severe hypoxaemia. *Transplantation* **57**, 224–228.
- Holt, R.I., Broide, E., Buchanan, C.R. *et al.* (1997) Orthotopic liver transplantation reverses the adverse nutritional changes of end-stage liver disease in children. *American Journal of Clinical Nutrition* **65**, 534–542.
- Horsmans, Y., Galant, C., Nicholas, M.L., Lamy, M. & Geubel, A.P. (1995) Failure of ribavirin or immunosuppressive therapy to alter the course of post-infantile giant-cell hepatitis. *Journal of Hepatology* **22**, 382.
- Hosey, M.T., Gordon, G., Kelly, D.A. & Shaw, L. (1995) Oral findings in children with liver transplants. *International Journal of Paediatric Dentistry* **5**, 29–34.
- Hubscher, S. (1996) Diagnosis and grading of liver allograft rejection: a European perspective. *Transplantation Proceedings* **28**, 504–507.
- Jain, A., Venkataramanan, R., Fung, J.J. *et al.* (1997) Pregnancy after liver transplantation under tacrolimus. *Transplantation* **64**, 559–565.
- Johnson, S.P., Leyendecker, J.R., Joseph, F.B. *et al.* (1996) Transjugular portosystemic shunts in paediatric patients awaiting liver transplantation. *Transplantation* **62**, 1178–1181.
- Kalayoglu, M., Stratta, R.J., Hoffmann, R.N. *et al.* (1988) Extended preservation of the liver for clinical transplantation. *Lancet* **i**, 617–619.
- Kelly, D.A. (1994a) Do H₂ receptor antagonists have a therapeutic role in childhood. *Journal of Pediatric Gastroenterology and Nutrition* **19**, 270–276.
- Kelly, D.A. (1994b) Organ transplantation for inherited metabolic disease. *Archives of Disease in Childhood* **71**, 181–183.
- Kelly, D.A. (1997) Posttransplant growth failure in children. *Liver Transplantation and Surgery* **3**, 1–9.
- Kelly, D.A. (2001) The use of anti-interleukin-2 receptor antibodies in paediatric liver transplantation. *Paediatric Transplantation* **5**, 386–389.
- Kelly, D., Jara, P., Rodeck, B. *et al.* (2002) Tacrolimus dual therapy versus Cyclosporin microemulsion triple therapy in paediatric liver transplantation: results from a multicentre randomised trial. *American Journal of Transplantation* **3**, 351.
- Keown, P., Kahan, B.D., Johnston, A. *et al.* (1998) Optimization of cyclosporine therapy with new therapeutic drug monitoring strategies: report from the International Neoral TDM Advisory Consensus Meeting (Vancouver, November 1997). *Transplantation Proceedings* **30**, 1645–1649.
- Kerker, N., Hadzi, N., Davies, E.T. *et al.* (1998). De-novo autoimmune hepatitis after liver transplantation. *Lancet* **351**, 409–413.
- Kuang, A.A., Rosenthal, P., Roberts, J.P. *et al.* (1996) Decreased mortality from technical failure improves results in paediatric liver transplantation. *Archives of Surgery* **131**, 887–892.
- Laifer, S.A. & Guido, R.S. (1995) Reproductive function and outcome of pregnancy after liver transplantation in women. *Mayo Clinic Proceedings* **70**, 388–394.
- Lauterberg, B.H., Vaishnar, Y., Stillwell, W.B. & Mitchell, J.R. (1980) The effects of age and glutathione depletion on hepatic glutathione turnover *in vivo* determined by acetaminophen probe analysis. *Journal of Pharmacological Experimental Therapy* **213**, 54–58.
- Lee, W., McKiernan, P., Beath, S., de Ville de Goyet, J. & Kelly, D. (2001) Fulminant hepatic failure in children in the United Kingdom: etiology and outcome. *Hepatology* **34**, 291A.
- Lilly, J.R. & Starzl, T.E. (1974) Liver transplantation in children with biliary atresia and vascular anomalies. *Journal of Paediatric Surgery* **9**, 707–714.
- Lindstedt, S., Holme, E., Lock, E. *et al.* (1992) Treatment of hereditary Tyrosinaemia Type I by inhibition of 4-hydroxyphenyl pyruvate dioxygenase. *Lancet* **340**, 813–817.
- Lucey, M.R., Graham, D.M., Martin, P. *et al.* (1992) Recurrence of hepatitis B and delta hepatitis after orthotopic liver transplantation. *Gut* **33**, 1390–1396.
- Macvicar, D., Dicks-Mireaux, C., Leonard, J.V. & Wight, D.G. (1990) Hepatic imaging with computed tomography of chronic tyrosinaemia type I. *British Journal of Radiology* **63**, 605–608.
- Mahadevan, S.B.K., McKiernan, P.J., Beath, S.V. & Kelly, D.A. (1999) Paracetamol hepatotoxicity in children. *Archives of Disease in Childhood* **80**, A21.
- Malatack, J.J., Schald, D.J., Urbach, A.H. *et al.* (1987) Choosing a paediatric recipient of orthotopic liver transplantation. *Journal of Paediatrics* **112**, 479–489.

400 Section 10: Transplantation

- Manowski, Z., Silver, M.M., Roberts, E.A., Superina, R.A. & Philips, M.J. (1990) Liver cell dysplasia and early liver transplantation in hereditary tyrosinaemia. *Modern Pathology* **36**, 694–701.
- McAlister, V.C., Peltekian, K.M., Malatjalian, D.A. *et al.* (2001) Orthotopic liver transplantation using low-dose Tacrolimus and sirolimus. *Liver Transplantation* **7**, 401–408.
- McDiarmid, S.V., Anand, R. & Lindblad, A.S. (2002) The Principal Investigators and Institutions of the Studies of Pediatric Liver Transplantation (SPLIT) Research Group. Development of a pediatric end-stage liver disease score to predict poor outcome in children awaiting liver transplantation. *Transplantation* **74**, 173–181.
- McKiernan, P.J., Permain, G.D., Johnson, T., Buckels, J.A., Mayer, A.D. & Kelly, D.K. (1992) Catch up growth in children following orthotopic liver transplantation. *Hepatology* **16**, 567.
- Mellon, A., Shepherd, R.W., Faoagali, J.L. *et al.* (1993) Cytomegalovirus infection after liver transplantation in children. *Journal of Gastroenterology and Hepatology* **8**, 540–544.
- Milkiewicz, P., Skiba, G., Kelly, D. *et al.* (2002) Transplantation for cystic fibrosis. Outcome following early liver transplantation. *Journal of Pediatric Gastroenterology and Nutrition* **17**, 208–213.
- Millis, J.M., Cronin, D.C., Brady, L.M. *et al.* (2000) Primary living-donor liver transplantation at the University of Chicago: technical aspects of the first 104 recipients. *Annals of Surgery* **232**, 104–111.
- Mirza, D.F., Achilleos, O., Pirrenne, J.A., Buckels, P., McMaster & Mayer, A.D. (1998) Encouraging results of split-liver transplantation. *British Journal of Surgery* **85**, 494–497.
- Mitzner, S.R., Strange, J., Klammt, S. *et al.* (2000) Improvement of hepatorenal syndrome with extracorporeal albumin dialysis MARS: results of a prospective randomized, controlled clinical trial. *Liver Transplantation* **6**, 277–286.
- Mohan, N., McKiernan, P., Preece, M.A., Green, A. & Kelly, D.A. (1999) Indications and outcome of liver transplantation in tyrosinaemia type I. *European Journal of Pediatrics* **158** (Suppl. 2), S49–54.
- Molmenti, E., Mazariegos, G., Bueno, T. *et al.* (1999) Noncompliance after paediatric liver transplantation. *Transplantation Proceedings* **31**, 408.
- Moukartzel, A.A., Najm, I., Vargas, J., McDiarmid, S.V., Busuttil, R.W. & Ament, M.E. (1990) Effect of nutritional status on outcome of orthotopic liver transplantation in paediatric patients. *Transplantation Proceedings* **22**, 1560–1563.
- Muiesan, P., Rela, M., Kane, P. *et al.* (1995) Liver transplantation for neonatal haemochromatosis. *Archives of Disease in Childhood* **73**, F178–F180.
- Murphy, M.S., Harrison, R., Davies, P. *et al.* (1996) Risk factors for liver rejection: evidence to suggest enhanced allograft tolerance in infancy. *Archives of Disease in Childhood* **75**, 502–506.
- Mutimer, D. (1999) Long term outcome of liver transplantation for viral hepatitis: is there a need to re-evaluate patient selection? *Gut* **45**, 475–476.
- Nazer, H., Ede, R.J., Mowat, A.P. & Williams, R. (1986) Wilson's disease: clinical presentation and use of prognostic index. *Gut* **27**, 1377–1381.
- Newell, K.A., Alonso, E.M., Whittington, P.F. *et al.* (1996) Posttransplant lymphoproliferative disease in paediatric liver transplantation. Interplay between primary Epstein–Barr virus infection and immunosuppression. *Transplantation* **62**, 370–375.
- Noujaim, H.M., Mayer, A.D., Buckels, J.A.C. *et al.* (2000) Techniques for and outcome of liver transplantation in neonates and infants up to 5 kg of body weight. In small children and those with aberrant vessels we often employ vascular conduits. *Journal of Pediatric Surgery* **37**, 159–164.
- Noujaim, H.M., Gunson, B., Mayer, D. *et al.* (2002) Ex-situ split liver transplantation. Impact of a new protocol. *Transplantation* **74**, 1386–1390.
- Nowicki, M.J., Ahmad, N., Heubi, J.E., Kuramoto, I.K., Baroudy, B.M. & Balistreri, W.F. (1994) The prevalence of hepatitis C virus (HCV) in infants and children after liver transplantation. *Digestive Diseases and Sciences* **39**, 2250–2254.
- O'Grady, J., Alexander, G., Hayllar, K.M. & Williams, R. (1989) Early indicators of prognosis in fulminant hepatic failure. *Gastroenterology* **97**, 439–445.
- O'Grady, J.G., Smith, H.M., Davies, S.E. *et al.* (1992) Hepatitis B virus reinfection after orthotopic liver transplantation. *Journal of Hepatology* **14**, 104–111.
- Oellerich, M., Burdelski, M., Lautz, H.U. *et al.* (1990) Lidocaine metabolite formation as a measure of liver function in patients with cirrhosis. *Therapeutic Drug Monitoring* **12**, 219–226.
- Pappas, P.A., Weppler, D., Pinna, A.D. *et al.* (2000) Sirolimus in paediatric gastrointestinal transplantation: the use of sirolimus for paediatric transplant patients with Tacrolimus-related cardiomyopathy. *Pediatric Transactions* **4**, 45–49.
- Pastore, M., Willems, M., Cornu, C. *et al.* (1995) Role of hepatitis C virus in chronic liver disease occurring after orthotopic liver transplantation. Clinical transplantation. *Archives of Disease in Childhood* **72**, 403–407.
- Pichlmayr, R., Ringe, B., Gubernatis, G. *et al.* (1988) Transplantation einer Spenderleber auf zwei Empfänger — eine neue Methode in der Weiterentwicklung der Lebersegmenttransplantation. *Langenbecks Archiv für Chirurgie* **373**, 127–130.
- Pimpalwar, A.P., Sharif, K., Ramani, P., Stevens, M., Grundy, R., Morland, B. *et al.* (2002) Strategy for hepatoblastoma management. Transplant versus non-transplant surgery. *Journal of Paediatric Surgery* **37**, 240–245.
- Raper, S.E., Grossman, M., Rader, D.J. *et al.* (1996) Safety and feasibility of liver-directed ex vivo gene therapy for homozygous familial hypercholesterolaemia. *Annals of Surgery* **223**, 116–126.
- Reinoso, M.A., Sharp, H.L. & Rank, J. (1997) Endoscopic variceal ligation of paediatric patients with portal hypertension secondary to liver cirrhosis. *Gastrointestinal Endoscopy* **46**, 244–246.
- Rela, M., Heaton, N.D., Vougas, V. *et al.* (1993) Orthotopic liver transplantation for hepatic complications of Wilson's disease. *British Journal of Surgery* **80**, 909–911.
- Rela, M., Muiesan, P., Andreani, P. *et al.* (1997) Auxiliary liver transplantation for metabolic diseases. *Transplantation Proceedings* **29**, 444–445.
- Rela, M., Muiesan, P., Bajtnagar, V. *et al.* (1996) Hepatic artery thrombosis after liver transplantation in children under 5 years of age. *Transplantation* **61**, 1355–1357.
- Renz, J.F., Lightdale, J., Mudge, C. *et al.* (1999) Mycophenolate mofetil, microemulsion Cyclosporin, and prednisolone as primary immunosuppression for pediatric liver transplant recipients. *Liver Transplantation Surgery* **5**, 136–143.

- Reyes, J., Jain, A., Mazariegos, G *et al.* (2000) Long-term results after conversion from cyclosporine to tacrolimus in pediatric liver transplantation for acute and chronic rejection. *Transplantation* **69**, 2578–2580.
- Riordan, S.M. & Williams, R. (1999) Tolerance after liver transplantation: does it exist and can immunosuppression be withdrawn. *Journal of Hepatology* **31**, 1106–1119.
- Rodeck, B., Melter, M., Hoyer, P.F., Ringe, B. & Brodehi, J. (1994) Growth in long-term survivors after orthotopic liver transplantation in childhood. *Transplantation Proceedings* **26**, 165–166.
- Rodeck, B., Melter, M., Kardorff, R. *et al.* (1996) Liver transplantation in children with chronic end stage liver disease; factors influencing survival after transplantation. *Transplantation* **62**, 1071–1076.
- Rodrigue, J.R., MacNaughton, K., Hoffman, R.G. III *et al.* (1996) Perceptions of parenting stress and family relations by fathers of children evaluated for organ transplantation. *Psychological Report* **79**, 723–727.
- Rosenthal, P., Emond, J.C., Heyman, M.B. *et al.* (1997) Pathological changes in yearly protocol liver biopsy specimens from healthy pediatric liver recipients. *Liver Transplantation and Surgery* **6**, 559–562.
- Ryckman, F.C., Flake, A.W., Fisher, R.A. *et al.* (1991) Segmental orthotopic hepatic transplantation as a means to improve patient survival and waiting-list mortality. *Journal of Paediatric Surgery* **26**, 422–427.
- Reinoso, M.A., Sharp, H.L. & Rank, J. (1997) Endoscopic variceal ligation in paediatric patients with portal hypertension secondary to liver cirrhosis. *Gastrointestinal Endoscopy* **46**, 244–246.
- Salcedo, M., Vaquero, J., Banares, R. *et al.* (2002) Response to steroids in de novo autoimmune hepatitis after liver transplantation. *Hepatology* **35**, 349–356.
- Sarna, S., Siplia, I., Vihervuori, E., Koistinen, R. & Holmberg, C. (1995) Growth delay after liver transplantation in childhood: studies of underlying mechanisms. *Pediatric Research* **38**, 366–372.
- Shamieh, I., Kibort, P.K., Suchy, F.J. & Freese, D.K. (1993) Antioxidant therapy for neonatal iron storage disease (NISD). *Pediatric Research* **33**, 109A.
- Sokal, E.M., Van Hoof, F., Alberti, D., de Ville de Goyet, J., de Barys, T. & Otte, J.B. (1992) Progressive cardiac failure following orthotopic liver transplantation for type IV glycogenosis. *European Journal of Pediatrics* **151**, 200–203.
- Stewart, S.M., Uauy, R., Waller, D., Kennard, B., Benser, M. & Andrews, W. (1989) Mental and motor development, social competence, and growth one year after successful pediatric liver transplantation. *Journal of Pediatrics* **114**, 574.
- Stone, R.D., Beasley, P.J., Treacy, S.J., Twente, A.W. & Vacanti, J.P. (1997) Children and families can achieve normal psychological adjustment and a good quality of life following pediatric liver transplantation: a long-term study. *Transplantation Proceedings* **29**, 1571–1572.
- Sudan, D.L., Langnas, A.N. & Shaw, B.W. Jr (1997) Long-term follow-up of auxiliary liver transplantation for fulminant hepatic failure. *Transplantation Proceedings* **29**, 485–486.
- Sudan, D.L., Shaw, B.W. Jr & Langnas, A.N. (1998) Causes of late mortality in pediatric liver transplant recipients. *Annals of Surgery* **227**, 289–295.
- Tanaka, K., Uemoto, S., Tokunaga, Y. *et al.* (1993) Liver transplantation in children from living-related donors. *Transplantation Proceedings* **25**, 1084–1086.
- Thomson, M., McKiernan, P., Buckels, J., Mayer, D. & Kelly, D. (1998) Generalised mitochondrial cytopathy is an absolute contraindication to orthotopic liver transplantation in childhood. *Journal of Pediatric Gastroenterology and Nutrition* **26**, 478–481.
- Tollemar, J., Hockerstedt, K., Ericzon, B., Jalanko, H. & Ringden, O. (1995) Liposomal amphotericin B prevents invasive fungal infections in liver transplant recipients. *Transplantation* **59**, 45–50.
- Uemoto, S., Vinomarta, Y., Tanarka, A. *et al.* (1996) Living related liver transplantation in children with hypoxaemia related to intrapulmonary shunting. *Transplantation International* **9** (Suppl. 1), S157–S159.
- Van Mourik, I.D.M., Beath, D. & Kelly, D. (2000) Long term nutrition and neurodevelopmental outcome of liver transplantation in infants aged less than 12 months. *Journal of Pediatric Gastroenterology and Nutrition* **30**, 269–276.
- Vincetil, F. (2002) What's in the pipeline? New immunosuppressive drugs in transplantation. *American Journal of Transplantation* **2**, 898–903.
- Viner, R.M., Forton, J.T.M., Cole, T.J., Clark, I.H., Nobel-Jamieson, G. & Barnes, N.D. (1999) Growth of long term survivors of liver transplantation. *Archives of Disease in Childhood* **80**, 235–240.
- Vons, C. (2001) Transplantation of isolated hepatocytes, is it an alternative for total liver transplantation? On the treatment of hereditary hepatic metabolic disease. *Journal de Chirurgie* **138**, 342–346.
- Watson, A.R. (2000) Non-compliance and transfer from paediatric to adult transplant unit. *Pediatric Nephrology* **14**, 469–472.
- Wayman, K.I., Cox, K.L. & Esquivel, C.O. (1997) Neurodevelopmental outcome of young children with extrahepatic biliary atresia 1 year after liver transplantation. *Journal of Pediatrics* **131**, 894–898.
- Whittington, P.F., Freese, D.K., Alonso, E.M., Schwarzenberg, S.J. & Sharp, H.L. (1994) Clinical and biochemical findings in progressive familial intrahepatic fibrosis. *Journal of Pediatric Gastroenterology and Nutrition* **18**, 134–141.
- Yandza, T., Gauthier, F. & Valayer, J. (1994) Lessons from the first 100 liver transplantations in children at Bicetre Hospital. *Journal of Pediatric Surgery* **29**, 905–911.
- Zitelli, B.J., Gartner, B., Malatack, J.J. *et al.* (1987) Pediatric liver transplantation: patient evaluation and selection, infectious complications, and life-style after transplantation. *Transplantation Proceedings* **19**, 3309–3316.